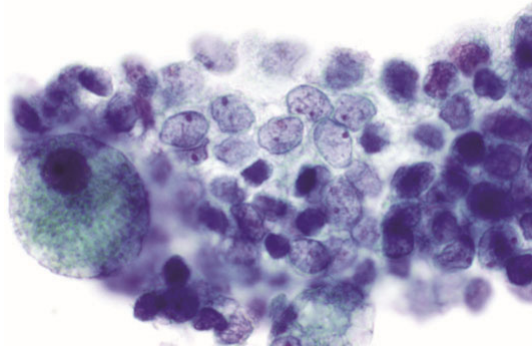


The “Atypical” Thyroid FNA: What’s AUS and What Isn’t?



Edmund S. Cibas, MD

Senior Pathologist,
Brigham and Women’s Hospital

Professor of Pathology,
Harvard Medical School
Boston, MA, USA

The 2023 Bethesda System for Reporting Thyroid Cytopathology

I. NONDIAGNOSTIC

II. BENIGN

III. ATYPIA OF UNDETERMINED SIGNIFICANCE


IV. FOLLICULAR NEOPLASM

- specify if oncocytic (formerly Hürthle cell) type

V. SUSPICIOUS FOR MALIGNANCY

VI. MALIGNANT

ATYPIA OF UNDETERMINED SIGNIFICANCE (AUS)



- For cases that don't fulfill criteria of other categories
- The findings raise concern for a neoplasm/malignancy, but the degree of atypia is not sufficient for an interpretation of follicular neoplasm or suspicious for malignancy.
- Criteria outlined in the Bethesda "blue book"
- Heterogeneous category
- Management: **repeat FNA, molecular testing, diagnostic lobectomy, or active surveillance**

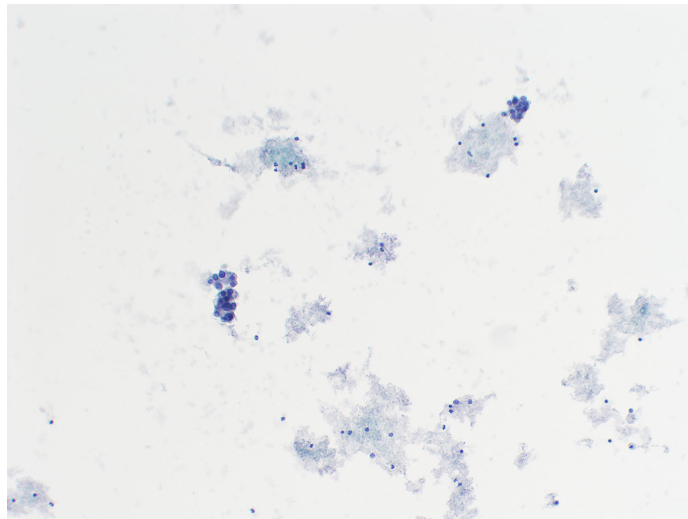
Qualifiers of AUS (2023)

- AUS with nuclear atypia*
- AUS, Other
 - architectural atypia
 - oncocytic type
 - atypical lymphoid cells
 - atypia, NOS

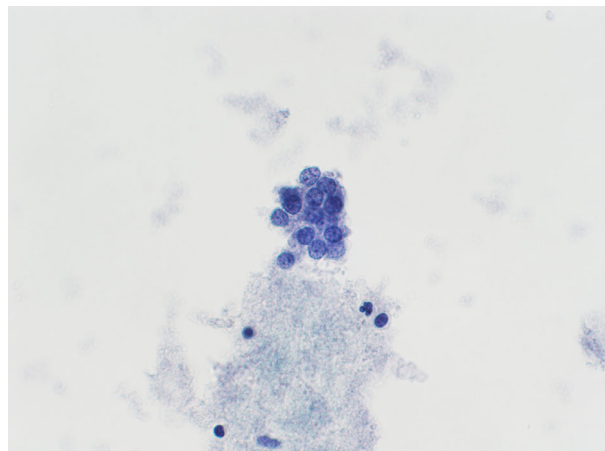
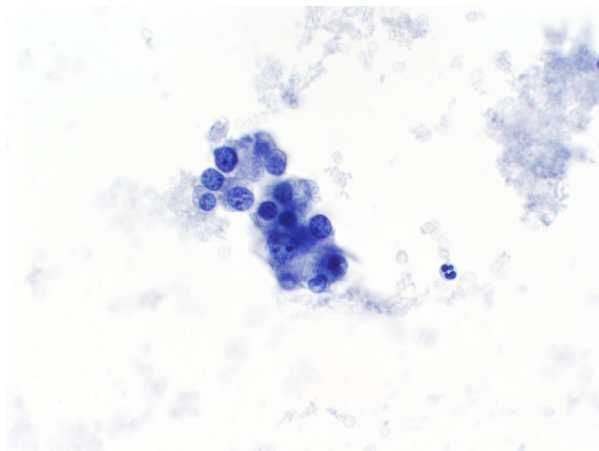
* formerly "cytologic atypia"

Up Next: 8 Cases – what is your diagnosis?

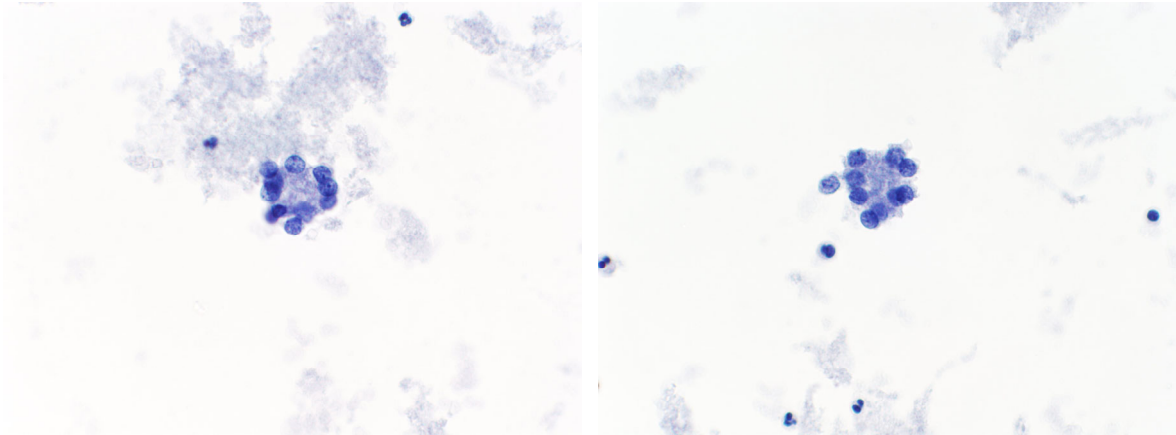
Case 1 (2012): 19 yo woman; 2.3 cm right thyroid nodule
“covers the entire right lobe”



Case 1: 19 yo woman; 2.3 cm right thyroid nodule
“covers the entire right lobe”



Case 1: 19 yo woman; 2.3 cm right thyroid nodule
“covers the entire right lobe”

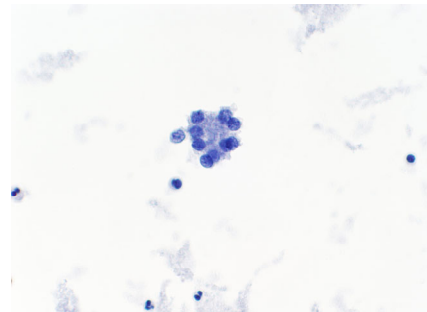


6 microfollicles total, otherwise acellular; colloid absent.

Case 1: 19 yo woman; 2.3 cm right thyroid nodule
“covers the entire right lobe”

What is your diagnosis?

- A. NONDIAGNOSTIC
- B. BENIGN
- C. AUS
- D. FOLLICULAR NEOPLASM

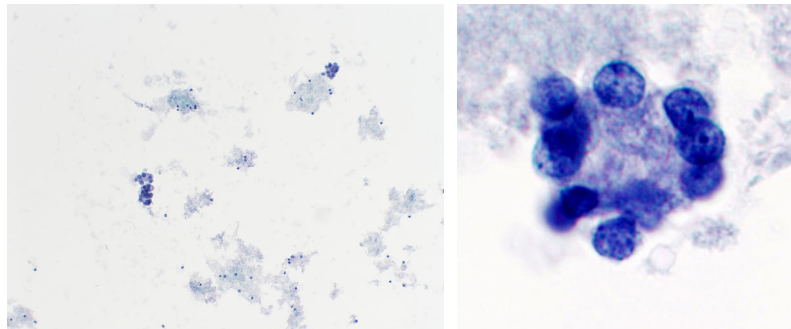


Case 1: 19 yo woman; 2.3 cm right thyroid nodule
“covers the entire right lobe”

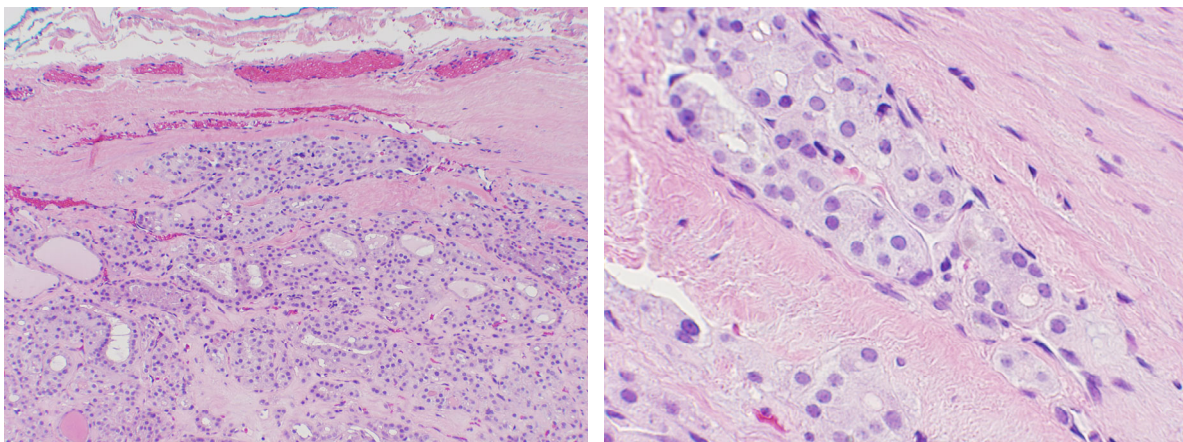
Our diagnosis:

ATYPIA OF UNDETERMINED SIGNIFICANCE.

Follicular cells with architectural atypia.

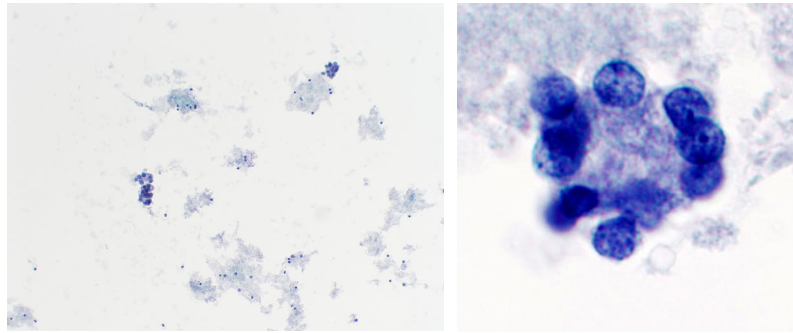


Case 1 follow-up (from 2012; pre-dates molecular testing):
Thyroidectomy → **Follicular carcinoma** (3cm), encapsulated, angioinvasive.
Alive and well 9 years later.

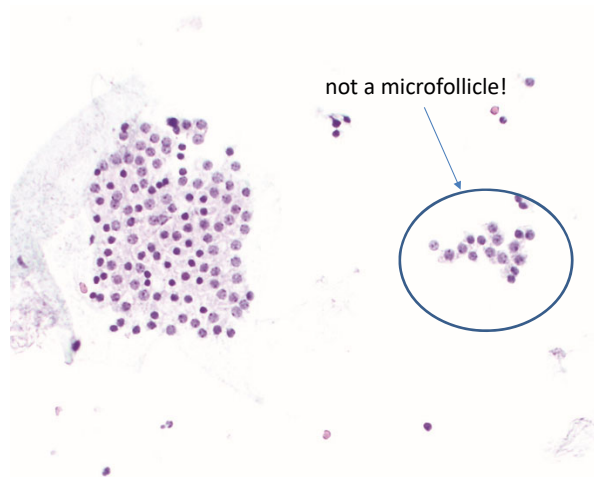


Why is Case 1 AUS?

- 1. Not benign or ND because of architectural atypia*
- 2. Not FN because too sparsely cellular*

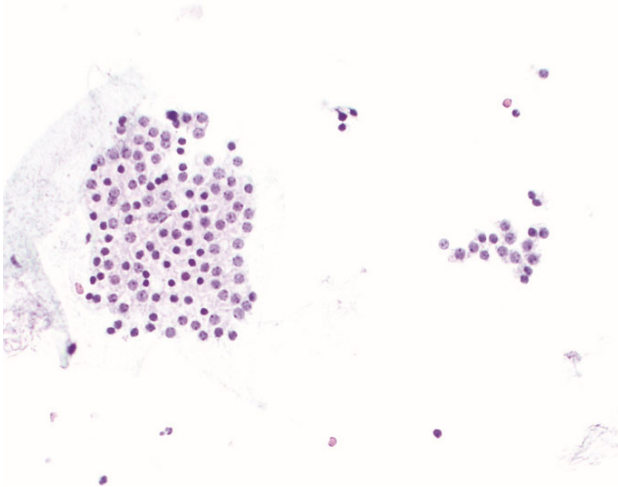


Benign (not AUS)

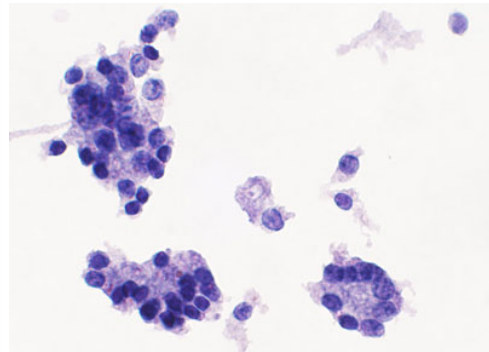


Macrofollicle fragments can be large or small.

Macrofollicles vs. Microfollicles

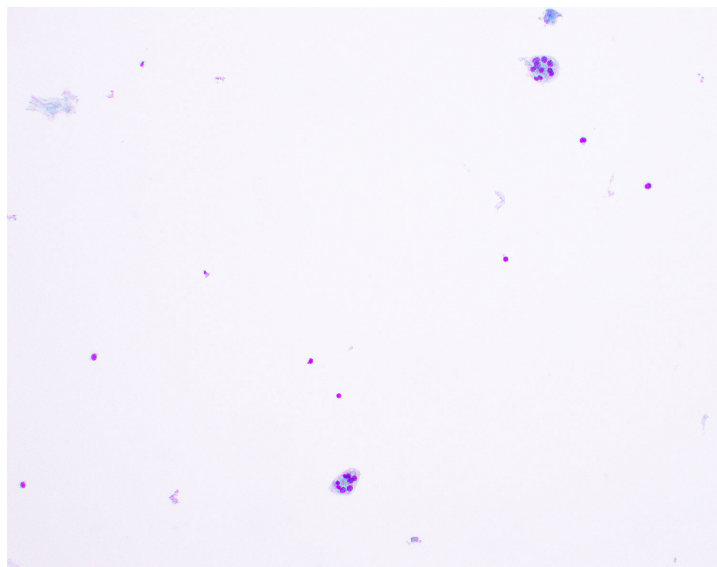


macrofollicles

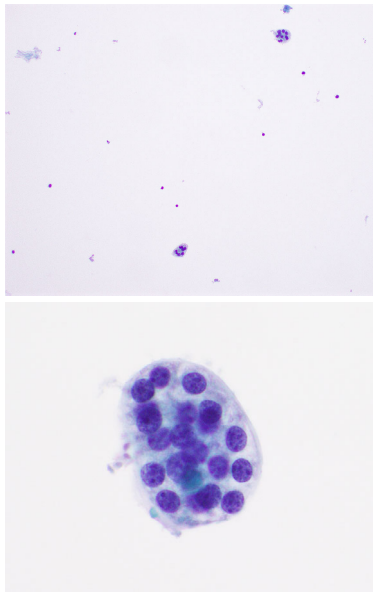
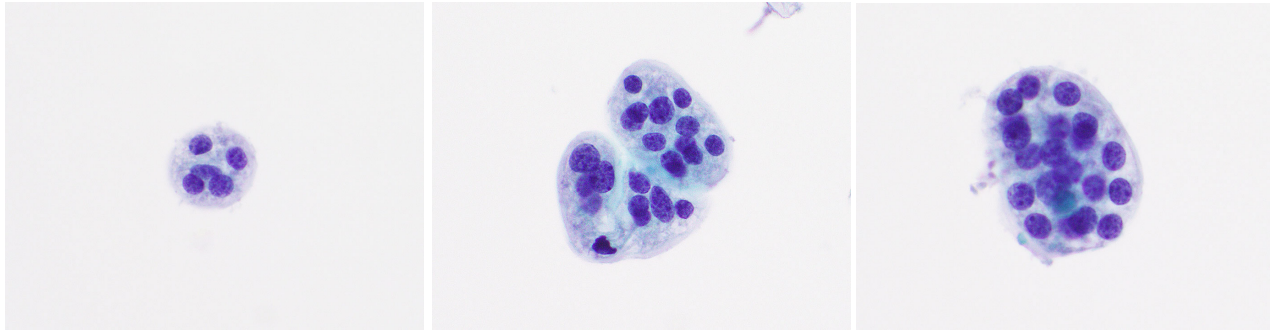


microfollicles

Case 2 (2014): 80 yo woman with 2.7 cm right thyroid nodule w/
microcalcifications. (Case from 2014.)



Case 2: 80 yo woman with 2.7 cm right thyroid nodule w/
microcalcifications. (Case from 2014.)



What is Your Diagnosis?

- A. Benign
- B. AUS
- C. FN

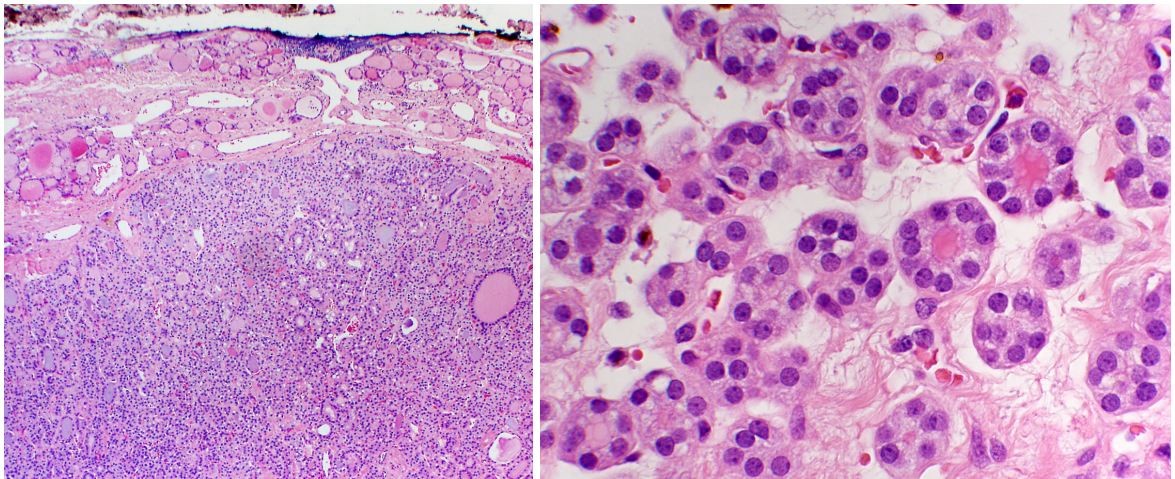
Case 2: 80 yo woman with 2.7 cm right thyroid nodule w/
microcalcifications. (Case from 2014.)

Our diagnosis (2014):

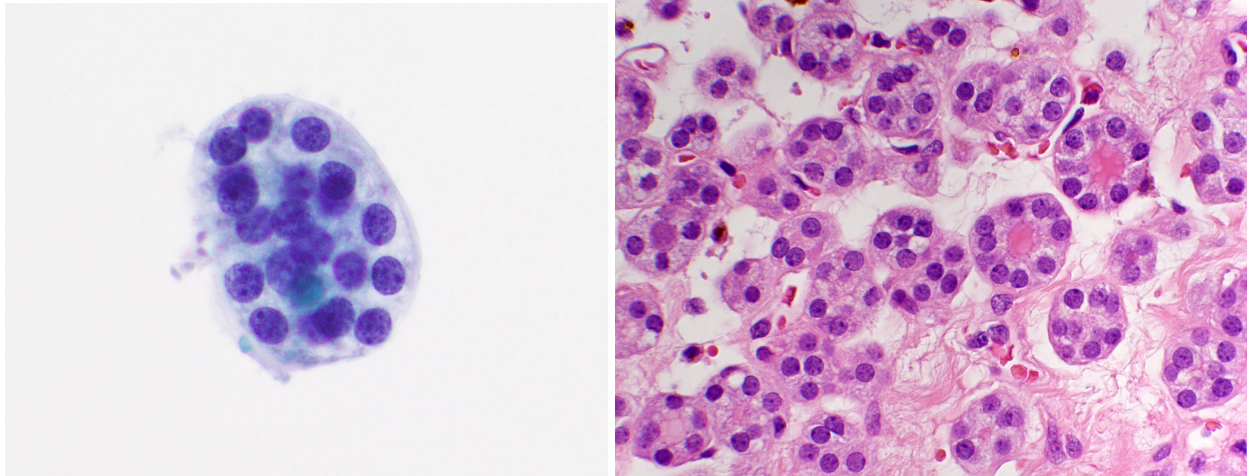
ATYPIA OF UNDETERMINED SIGNIFICANCE.

Follicular cells with architectural atypia.

Case 2 follow-up: Lobectomy: Adenomatous nodule.
Alive and well 9 years later (age 89).



Follow-up: Lobectomy: Adenomatous nodule.
Alive and well 8 years later (age 88).



Case 2: 80 yo woman with 2.7 cm right thyroid nodule w/
microcalcifications. (Case from 2014)

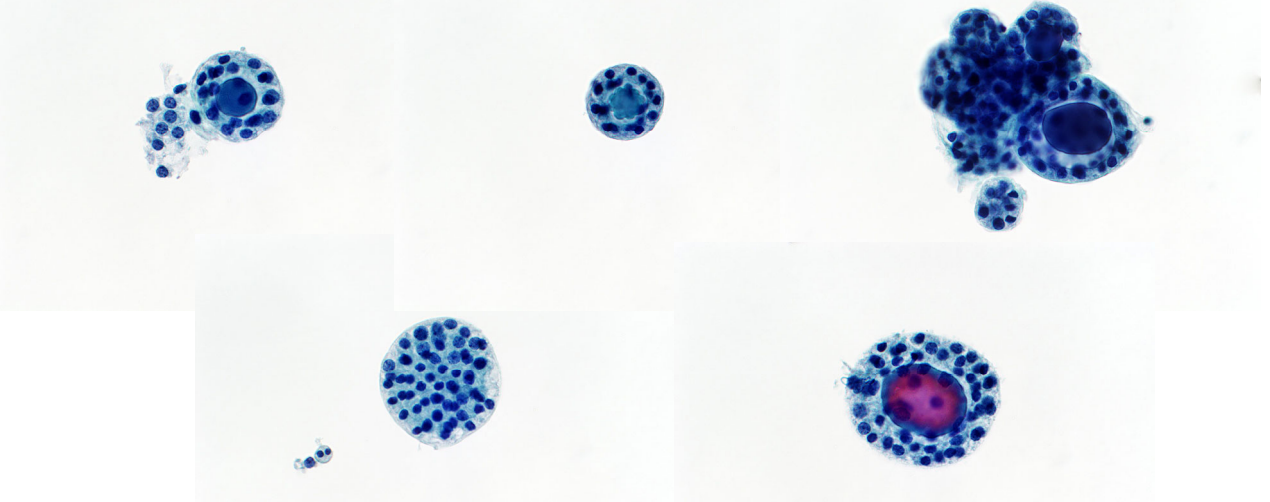
Diagnosis I would make today (2025):

BENIGN.

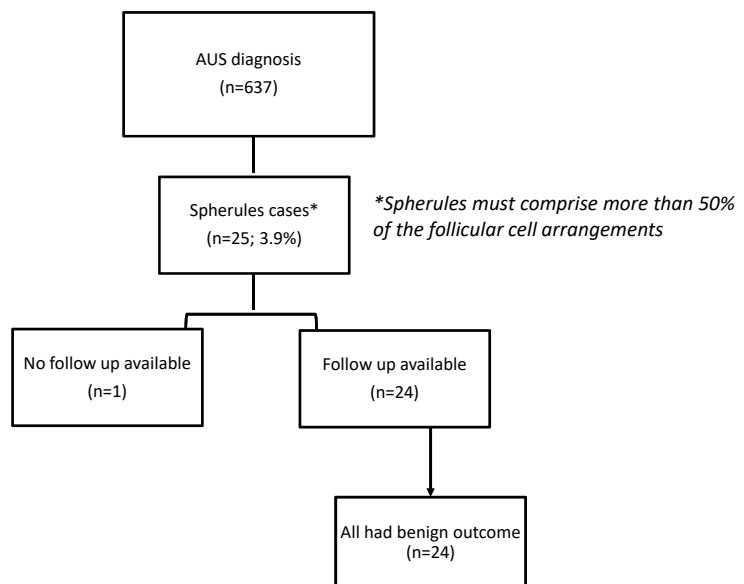
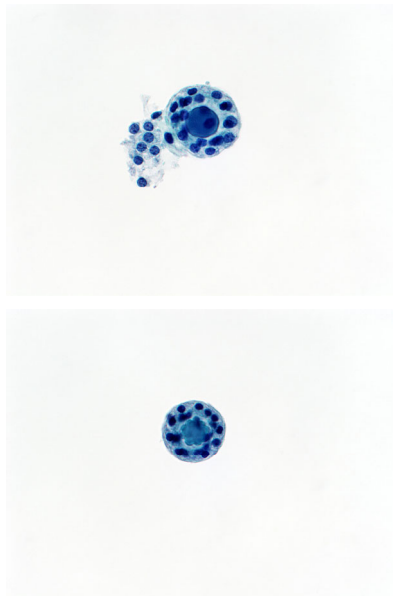
Consistent with a benign follicular nodule.

Different case - 36 yo woman (case from 2016) – also called AUS

Repeat FNA was benign; repeat U/S 2 years later showed no change in nodule size.

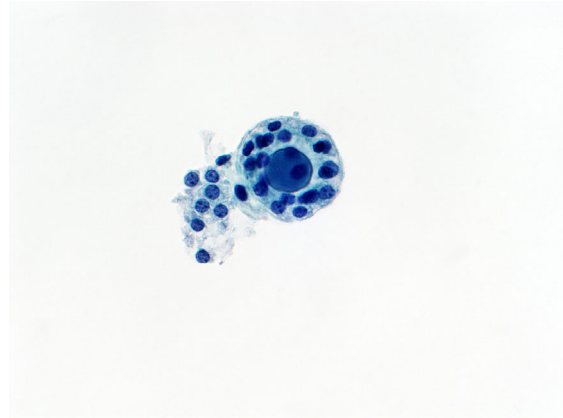

So We Embarked on a Study...



Follow Up of Spherule Cases



- 24/25 cases (96%) had follow-up
- Benign follow-up in all 24 cases:
 - benign histology (7)
 - benign Afirma (8)
 - benign repeat FNA (5)
 - stable U/S findings (4)



Original Article

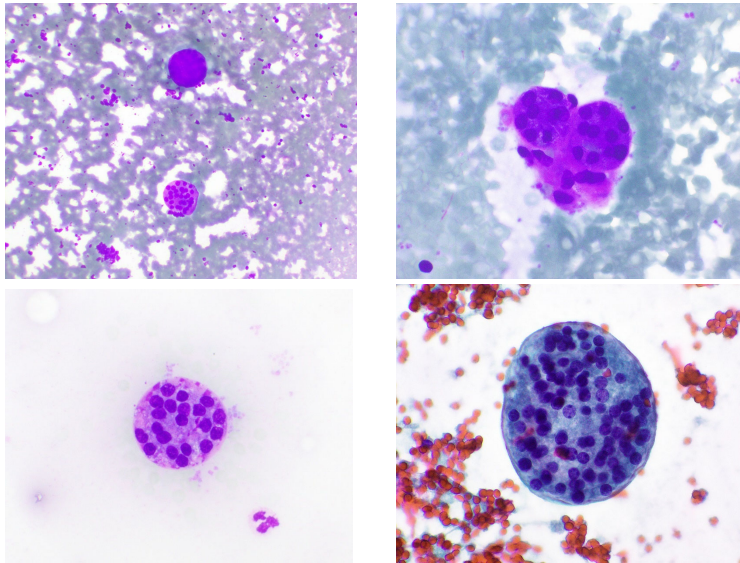
Cancer Cytopathol 2020

Defining Thyroid Spherules: A Benign Cytomorphologic Feature That Mimics Microfollicles

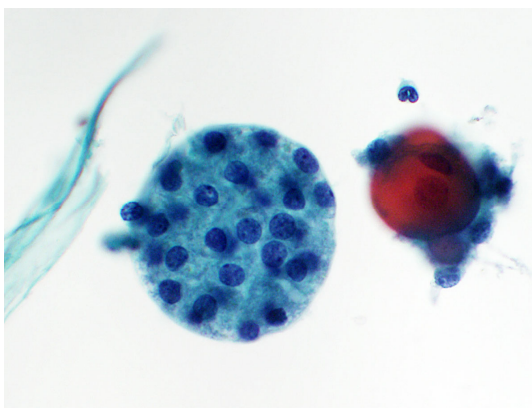
Danielle C. Costigan, MD ¹; Mohanad Shaar, MD¹; Mary C. Frates, MD²; Erik K. Alexander, MD³; Justine A. Barletta, MD¹; and Edmund S. Cibas, MD ¹

BACKGROUND: Distinctive rounded structures termed *spherules* have been observed in thyroid fine-needle aspiration (FNA) samples. Although they are often small and interpreted as microfollicles, spherules are notable for the even spacing of the follicular cells along the perimeter of the structure. Because they have an orderly architectural arrangement, it has been hypothesized that spherules are benign and do not carry the same risk of malignancy that traditional microfollicles do. The aim of this study was to identify the clinical significance and histopathologic correlates of spherules. **METHODS:** Thyroid

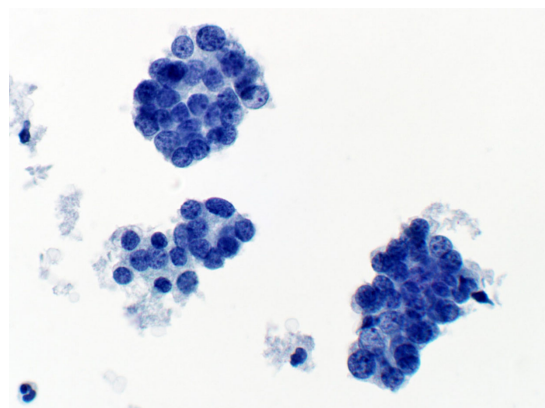
Spherules also seen on smears (74 yo F, solitary L thyroid nodule)



How Can I Distinguish Spherules from “True” Microfollicles?



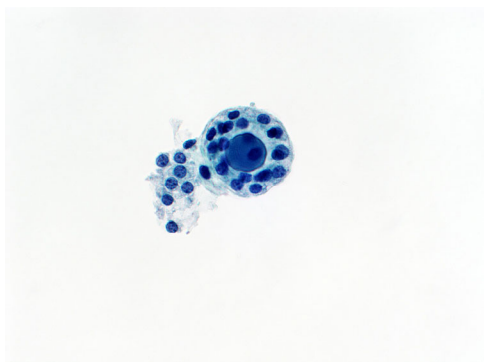spherule



true microfollicles

Figure 5 from Costigan et al

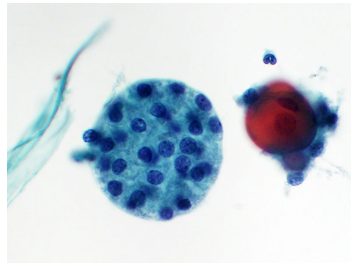
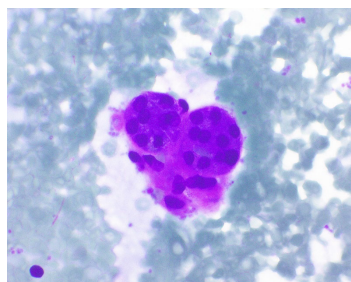
Recognizing Spherules



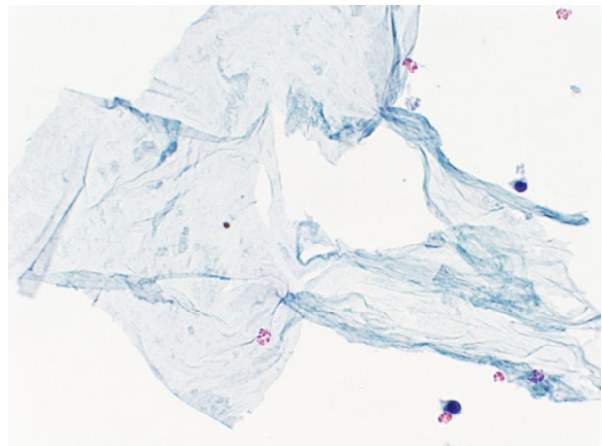
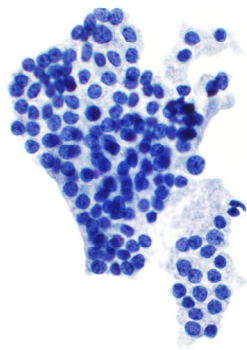
- Samples are sparsely or only moderately cellular
- Clusters:
 - Sharply outlined, round contour
 - Evenly spaced nuclei
 - Can be multilayered

Spherules: Take-Home Message

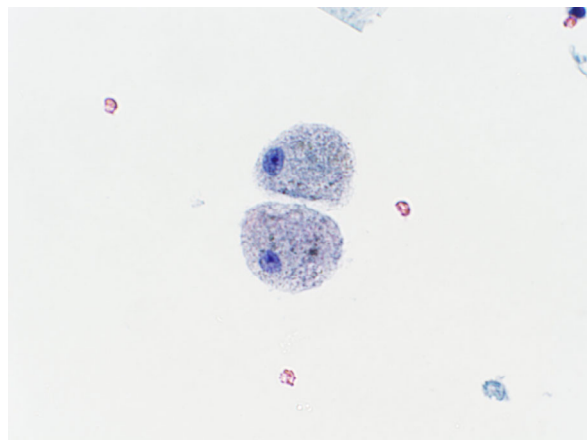
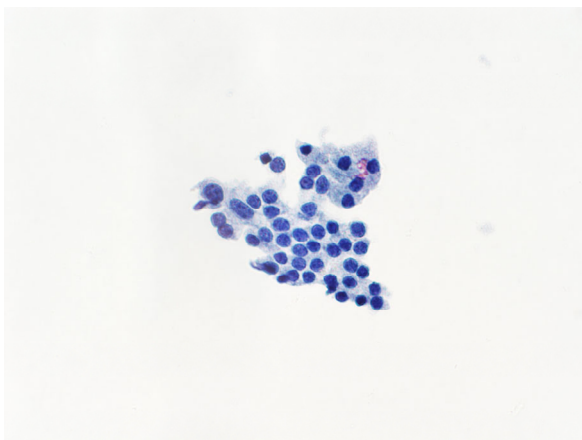
- Spherules can and should be distinguished from microfollicles.
- Spherules have sharply defined contours and evenly spaced nuclei.
- Even though spherules are “small,” they appear to have a different biology from true microfollicles.
- A spherules case can and should be called benign.
- You can reduce your AUS rate by 4%.



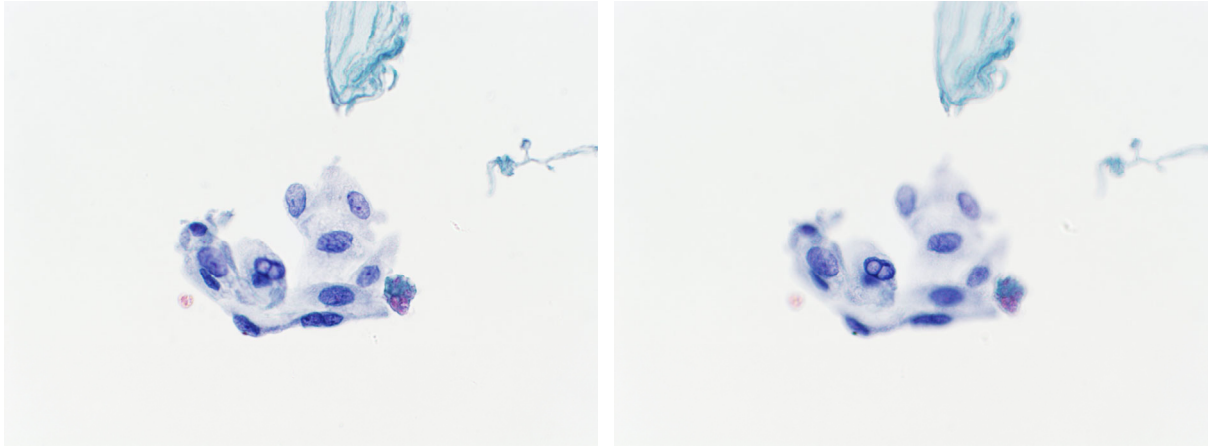
Case 3: 76 yo woman with a 3.4 cm isthmic nodule.
Previous FNA benign; now slightly larger.



Case 3: 76 yo woman with a 3.4 cm isthmic nodule.
Previous FNA benign; now slightly larger.



Case 3: 76 yo woman with a 3.4 cm isthmic nodule.
Previous FNA benign; now slightly larger.



Case 3: 76 yo woman with a 3.4 cm isthmic nodule.
Previous FNA benign; now slightly larger.

What is your diagnosis?

- A. NONDIAGNOSTIC
- B. BENIGN
- C. AUS
- D. SUSPICIOUS FOR PAPILLARY CARCINOMA

Case 3: 76 yo woman with a 3.4 cm isthmic nodule.
Previous FNA benign; now slightly larger.

What is your diagnosis?

A. NONDIAGNOSTIC

B. BENIGN

C. AUS

D. SUSPICIOUS FOR PAPILLARY CARCINOMA

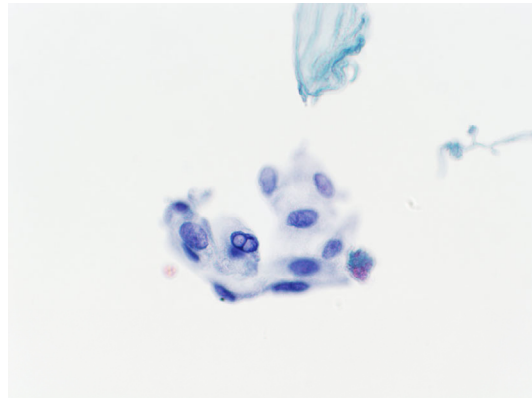
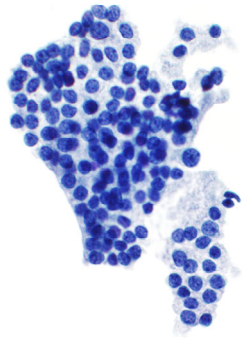
Case 3: 76 yo woman with a 3.4 cm isthmic nodule.
Previous FNA benign; now slightly larger.

Our diagnosis:

BENIGN.

Benign-appearing follicular cells, colloid, macrophages,
and cyst lining cells.

Case 3 follow-up: Alive and well 14 years later (91 yo)

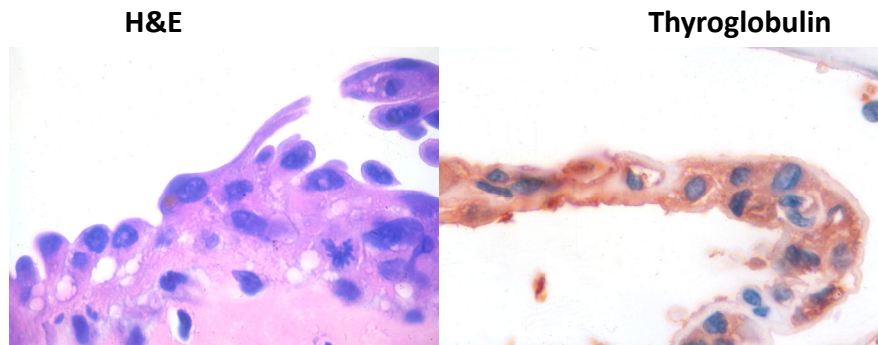


What are “Cyst Lining Cells?”

- Reactive/reparative thyroid follicular cells
- Cytomorphology
 - Flat sheets
 - Large cells with an elongated shape
 - Distinct cell borders
 - Abundant cytoplasm
 - Inclusions are occasionally present
- Most are easily recognized as benign
- But sometimes the degree of atypia is sufficient for a dx of AUS

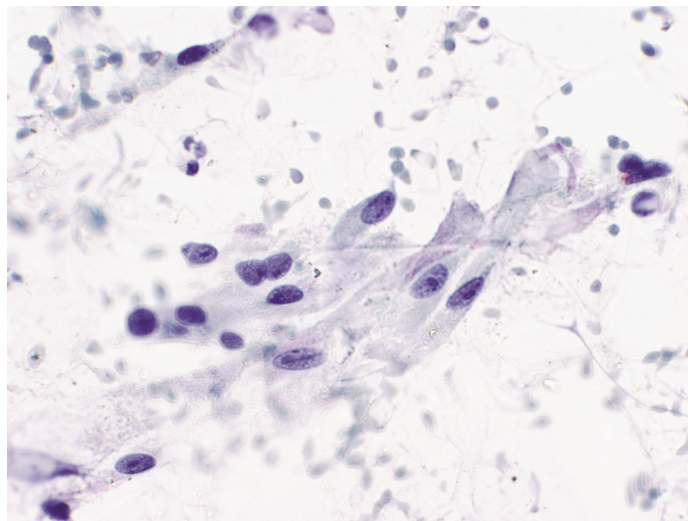
Faquin WC et al, Cancer Cytopathol 2005; 105: 71-9.

Histopathology of Cyst Lining Cells

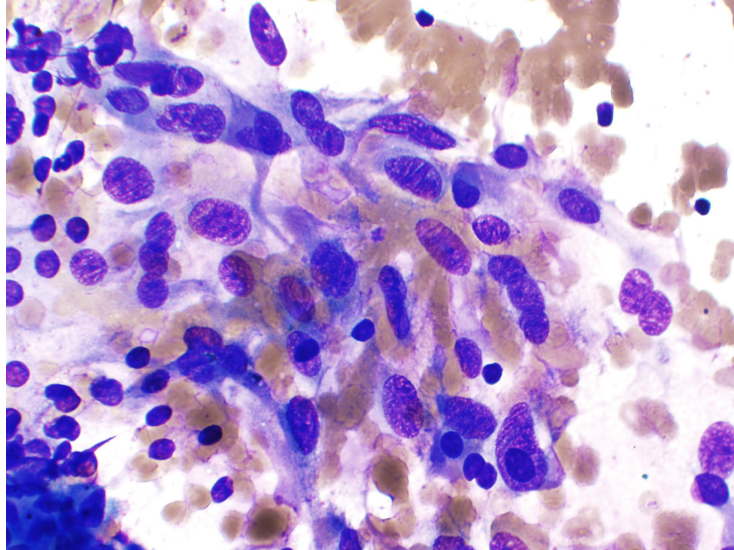


Faquin WC et al, Cancer Cytopathol 2005; 105: 71-9.

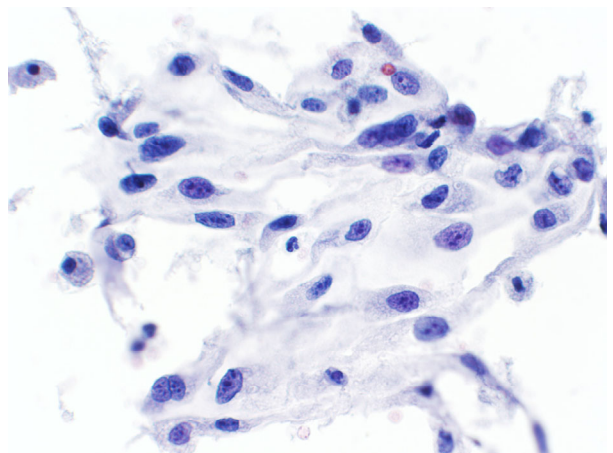
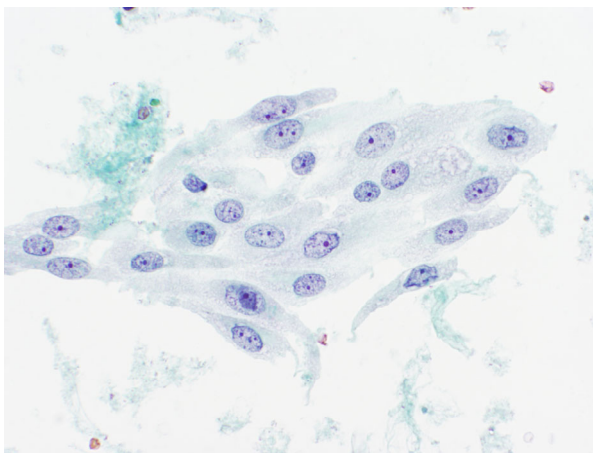
Cyst Lining Cells



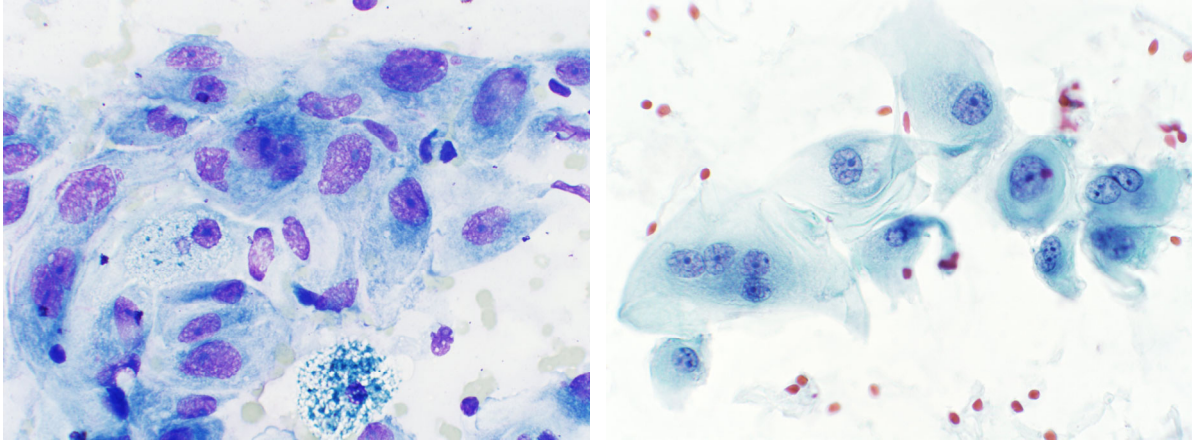
Cyst Lining Cells



Cyst Lining Cells



Cyst Lining Cells



Usually few in number, in a background of benign follicular cells and colloid

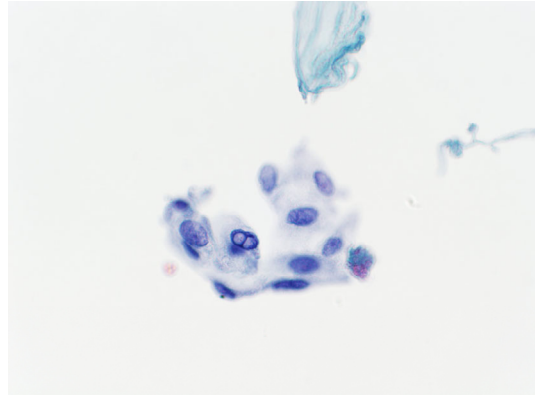
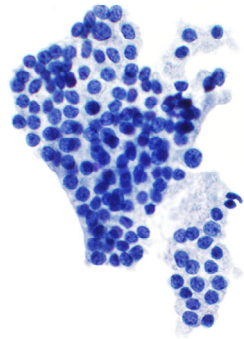
Case 3: 76 yo woman with a 3.4 cm isthmic nodule.
Previous FNA benign; now slightly larger.

BENIGN.

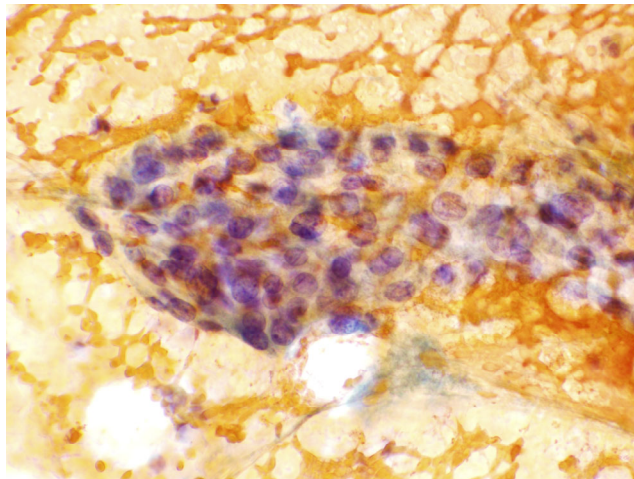
Benign-appearing follicular cells, colloid, macrophages,
and **cyst lining cells**.

Why is Case 3 benign?

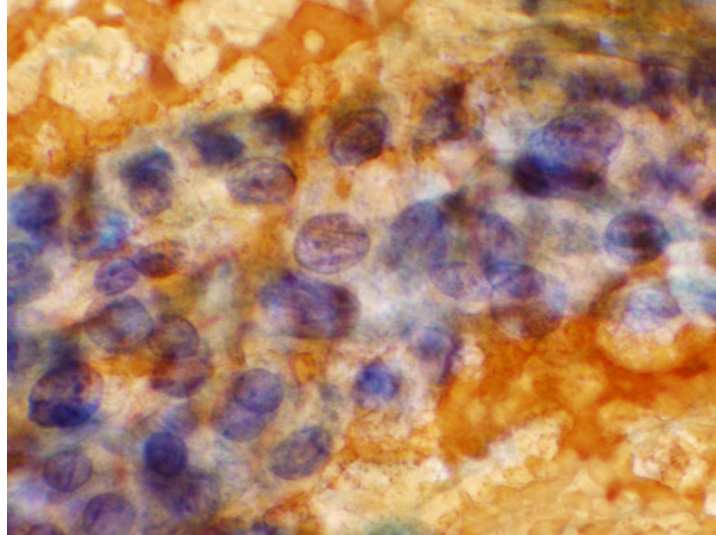
- 1. Cyst lining cells, despite their atypical features, are benign*
- 2. Learning to recognize them can help reduce the rate of AUS*



**Case 4: 79 yo man with a history of lung cancer
and a PET-avid thyroid gland**



Case 4: 79 yo man with a history of lung cancer
and a PET-avid thyroid gland



Case 4: 79 yo man with a history of lung cancer
and a PET-avid thyroid gland

What is your diagnosis?

- A. NONDIAGNOSTIC
- B. BENIGN
- C. AUS
- D. SUSPICIOUS FOR PAPILLARY CARCINOMA

Case 4: 79 yo man with a history of lung cancer and a PET-avid thyroid gland

My diagnosis:

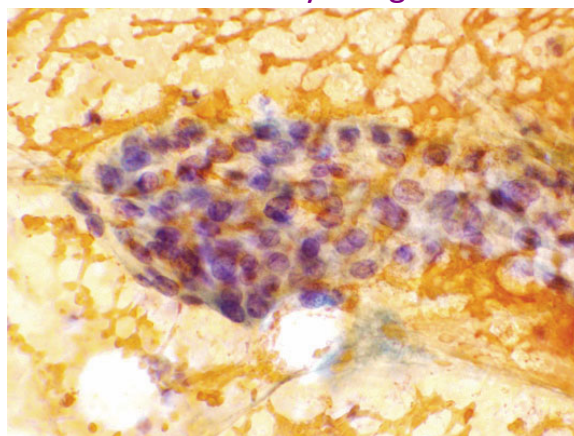
ATYPIA OF UNDETERMINED SIGNIFICANCE.

Virtually acellular specimen.

Rare follicular cells with cytologic atypia, but too few and too obscured by blood for further evaluation.

(Personal consult from Los Angeles; no follow-up available.)

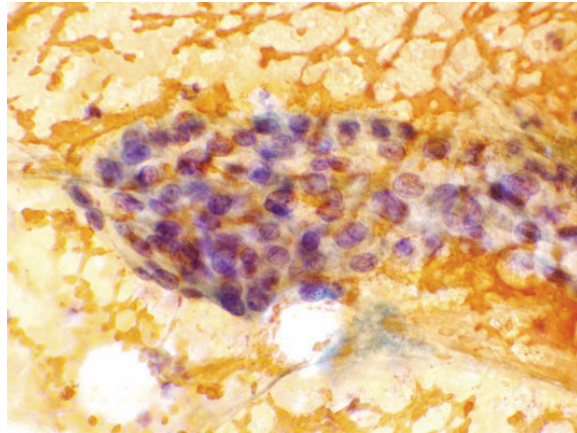
Case 4: 79 yo man with a history of lung cancer and a PET-avid thyroid gland



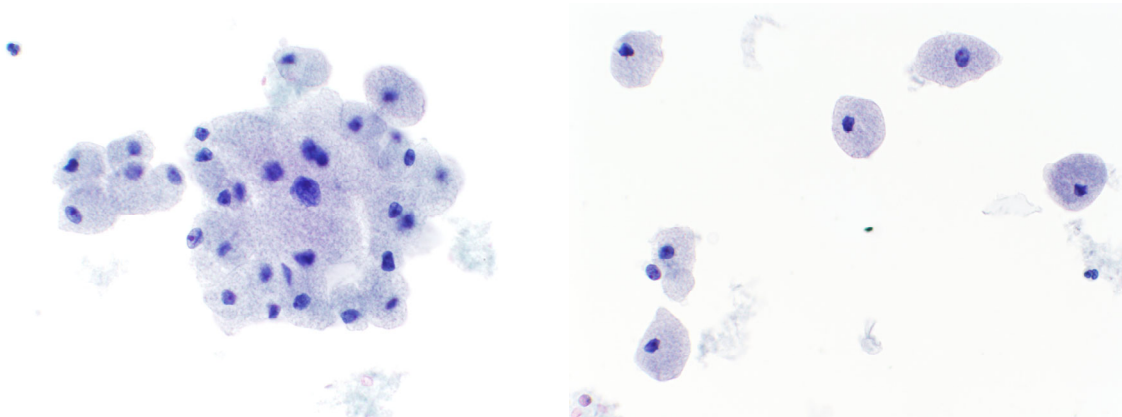
Atypia associated with obscuring blood
NOTE: Blood and/or clotting alone are **not** sufficient
for an interpretation of AUS.

Why is Case 4 AUS?

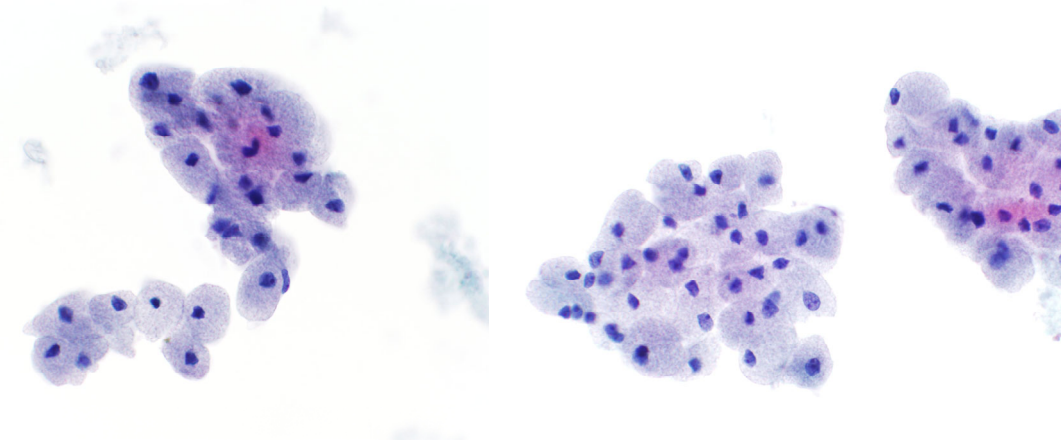
- 1. Not ND or benign because there is nuclear atypia.*
- 2. Not suspicious for malignancy because the sample is so limited.*



Case 5: 53 yo woman with Hashimoto thyroiditis.
1.8 cm right thyroid nodule.



Case 5: 53 yo woman with Hashimoto thyroiditis.
1.8 cm right thyroid nodule.



Case 5: 53 yo woman with Hashimoto thyroiditis.
1.8 cm right thyroid nodule.

What is your diagnosis?

- A. NONDIAGNOSTIC
- B. BENIGN
- C. AUS
- D. ONCOCYTIC FOLLICULAR NEOPLASM

Case 5: 53 yo woman with Hashimoto thyroiditis.
1.8 cm right thyroid nodule.

What is your diagnosis?

- A. NONDIAGNOSTIC
- B. BENIGN
- C. AUS
- D. ONCOCYTIC FOLLICULAR NEOPLASM

Case 5: 53 yo woman with Hashimoto thyroiditis.
1.8 cm right thyroid nodule.

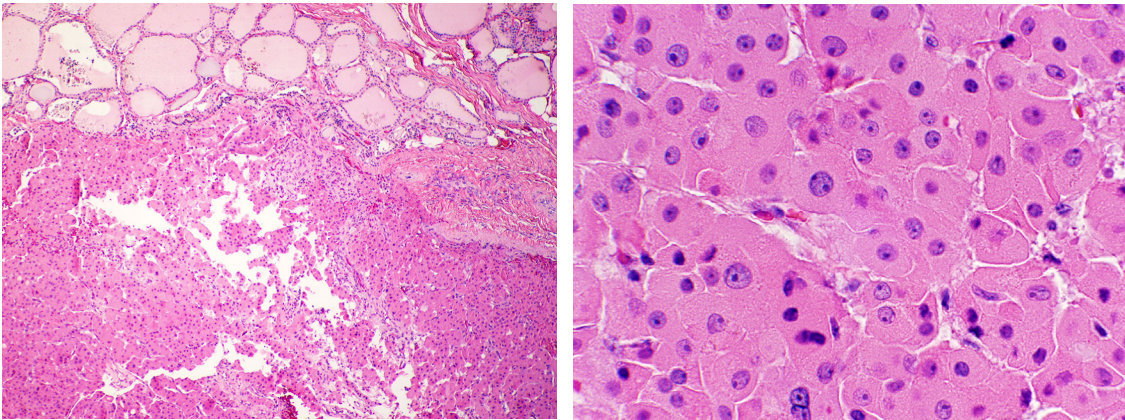
Our diagnosis (2010):

ATYPIA OF UNDETERMINED SIGNIFICANCE.

NOTE: In a patient with Hashimoto thyroiditis, the findings may represent an adenomatous nodule with oncocytic changes. However, an oncocytic follicular neoplasm cannot be entirely excluded.

Case 5 follow-up:

Thyroidectomy 2 months later→ **Follicular thyroid carcinoma, oncocytic type (1.2 cm)**, minimally invasive (complete transgression of capsule). Alive and well 15 years later.



**Case 5: 53 yo woman with Hashimoto thyroiditis.
1.8 cm right thyroid nodule.**

In the Bethesda System, a moderately or markedly cellular sample composed of a virtually exclusive population of oncocytic cells can be called either **AUS** or **Oncocytic Follicular Neoplasm** if the clinical setting suggests a benign oncocytic nodule, e.g.,

- Hashimoto thyroiditis
- multinodular goiter

Does a history of Hashimoto thyroiditis affect the positive predictive value of an Oncocytic Follicular Neoplasm diagnosis by FNA?

- 401 “Hürthle Cell Neoplasm” FNA cases
- overall malignancy rate = 24%

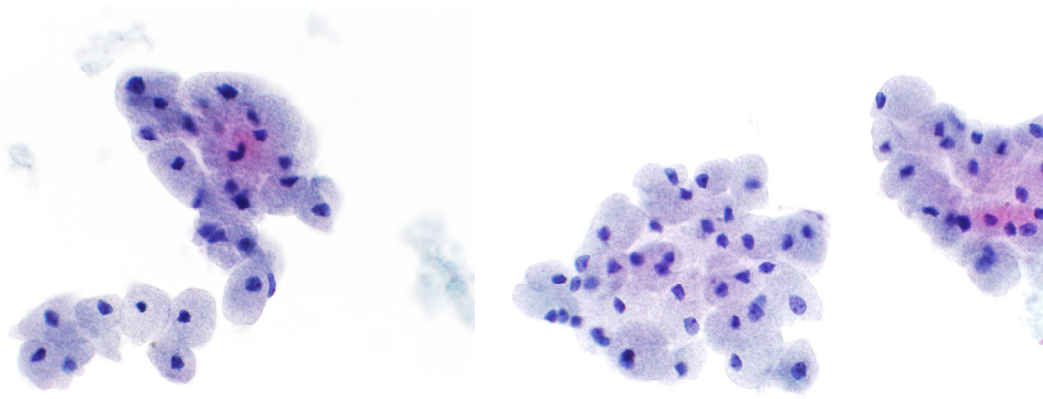
Hashimoto?	n	Malignant
No	266	67 (25%)
Yes	21	2 (9.5%)

Roh et al, **Am J Clin Pathol** 2011; 135: 139-45.

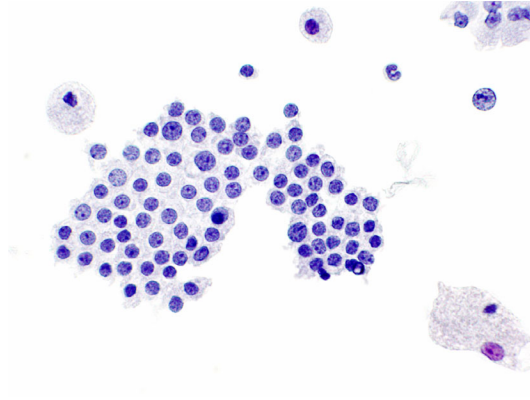
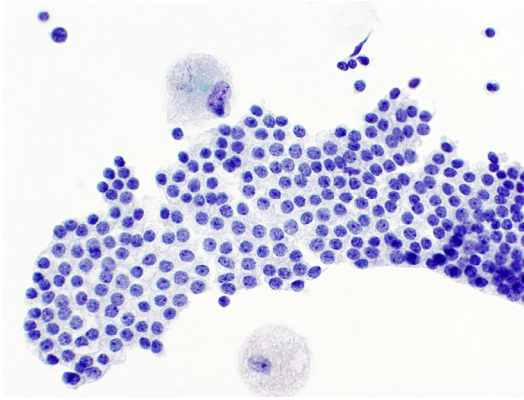
Why is Case 5 AUS?

A cellular sample comprised exclusively of oncocytes in a patient with Hashimoto's can be interpreted as either AUS or FN.

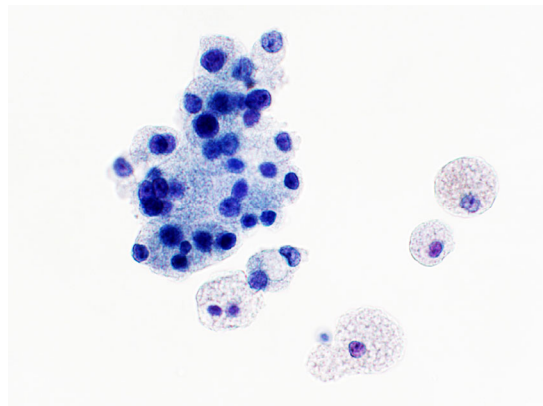
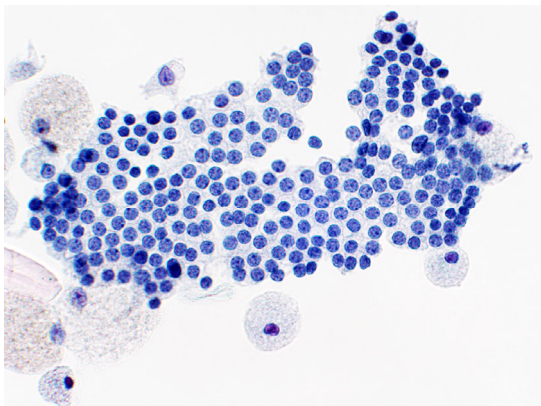
(Note, that HT does not exclude the possibility of an oncocytic FC.)



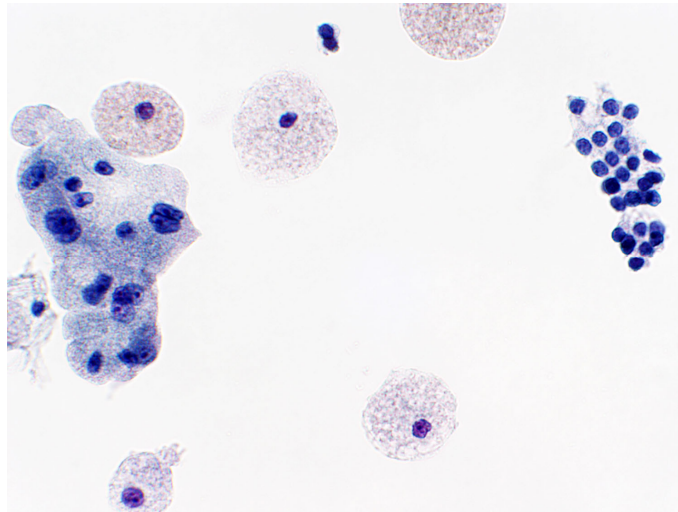
Case 6 (2008): 64 yo woman with multiple thyroid nodules.
3.0 cm left nodule. Previous FNA (5 yrs ago) benign, but interval growth.



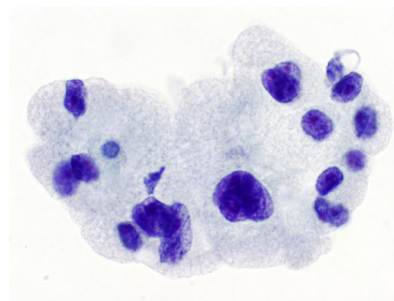
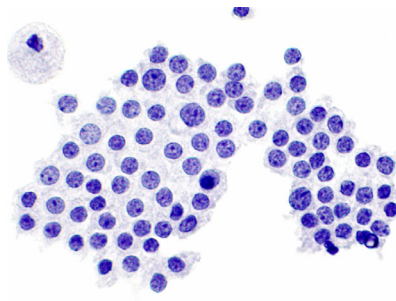
Case 6: 64 yo woman with multiple thyroid nodules.
3.0 cm left nodule. Previous FNA (5 yrs ago) benign, but interval growth.



Case 6: 64 yo woman with multiple thyroid nodules.
3.0 cm left nodule. Previous FNA (5 yrs ago) benign, but interval growth.



Case 6: 64 yo woman with multiple thyroid nodules.
3.0 cm left nodule. Previous FNA (5 yrs ago) benign, but interval growth.



Case 6: 64 yo woman with multiple thyroid nodules.
3.0 cm left nodule. Previous FNA (5 yrs ago) benign, but interval growth.

What is your diagnosis?

- A. NONDIAGNOSTIC
- B. BENIGN
- C. AUS
- D. ONCOCYTIC FOLLICULAR NEOPLASM

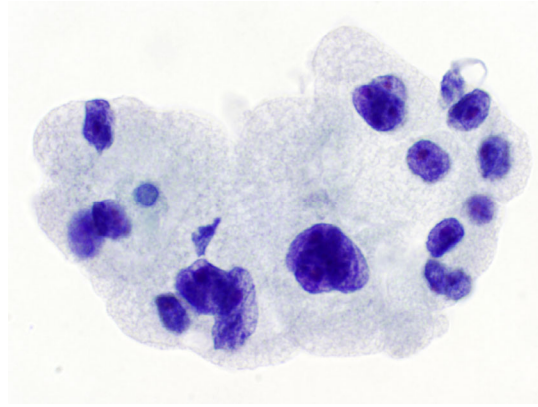
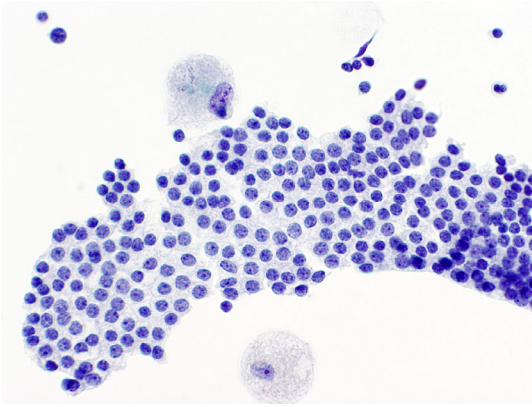
Case 6: 64 yo woman with multiple thyroid nodules.
3.0 cm left nodule. Previous FNA (5 yrs ago) benign, but interval growth.

Our diagnosis:

BENIGN.

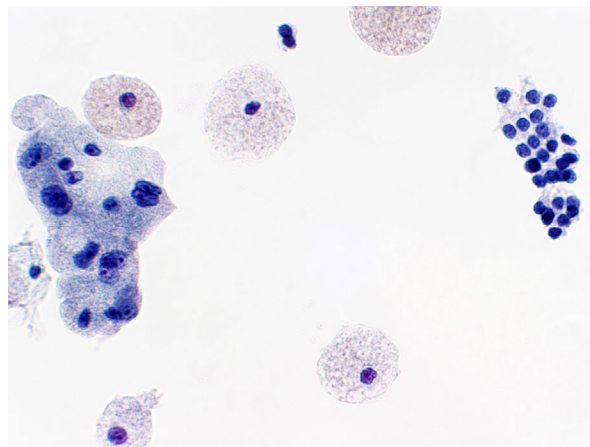
Benign-appearing follicular cells and oncocytes,
consistent with a benign thyroid nodule.

Case 6 follow-up: Alive and well 17 years later (age 81).

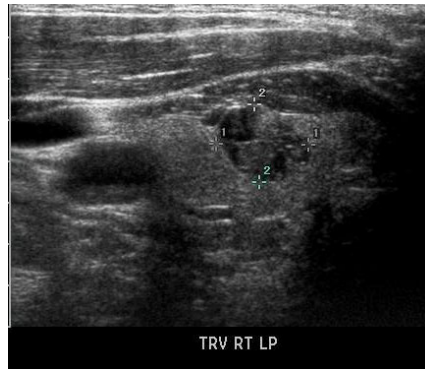


Why is Case 6 not AUS?

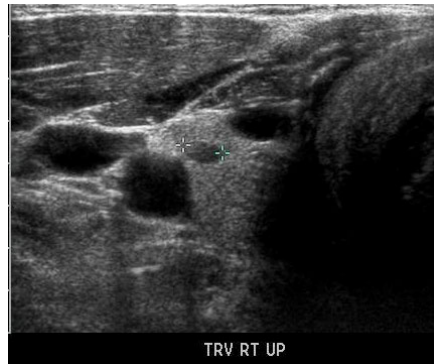- 1. Focal oncocytic metaplasia is common in benign thyroid nodules.*
- 2. An FNA that's a mix of follicular cells and oncocytic cells is benign.*



Case 7 (2005): 53 yo M with hypercalcemia.
U/S shows multiple small right thyroid nodules.

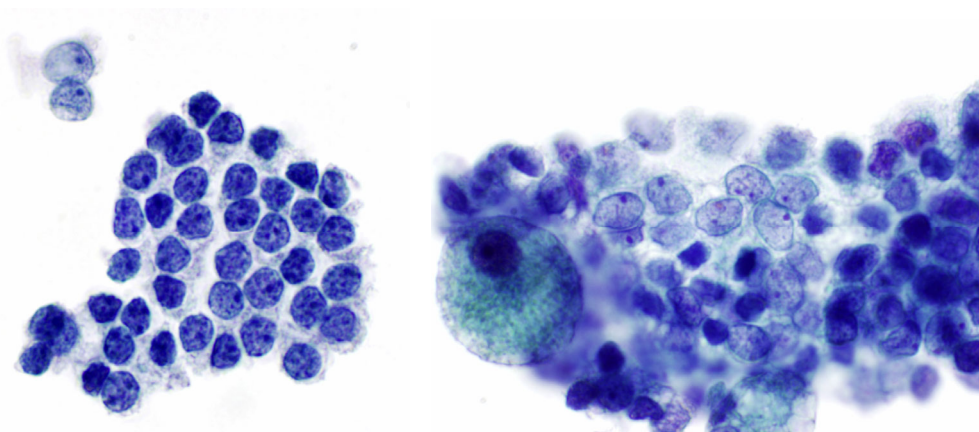


1.1 cm R/LP nodule, <25% cystic (biopsied)



0.5 cm RUP nodule (not biopsied)

Case 7: 53 yo male with a 1.1. cm right thyroid nodule



Case 7: 53 yo male with a 1.1 cm right thyroid nodule

What is your diagnosis?

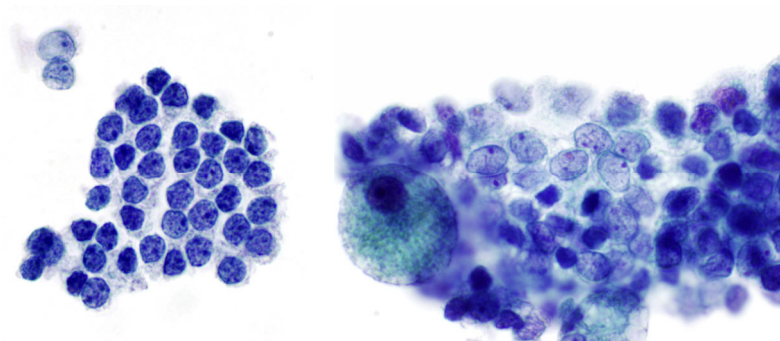
- A. NONDIAGNOSTIC
- B. BENIGN
- C. AUS
- D. SUSPICIOUS FOR PAPILLARY CARCINOMA

Case 7: 53 yo male with a 1.1 cm right thyroid nodule

Our diagnosis:

ATYPIA OF UNDETERMINED SIGNIFICANCE.

Follicular cells with focal nuclear atypia.



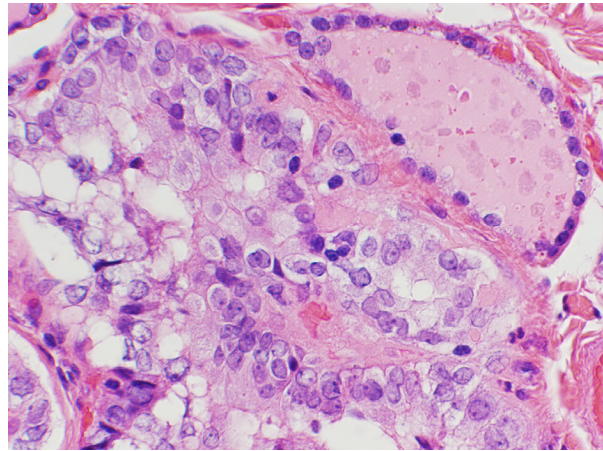
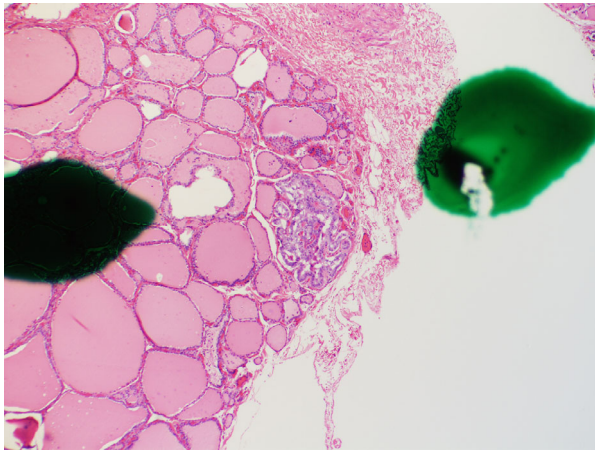
Case 7 follow-up: Repeat FNA 3 months later also AUS.

Right lobectomy:

Adenomatoid nodule.

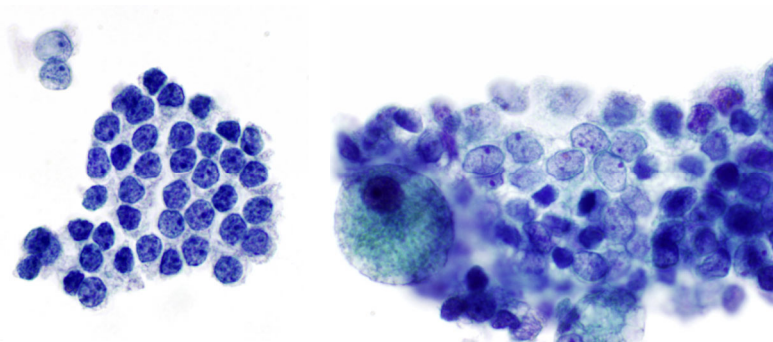
Multifocal papillary thyroid microcarcinoma (largest focus 3 mm).

Alive and well 16 years later.

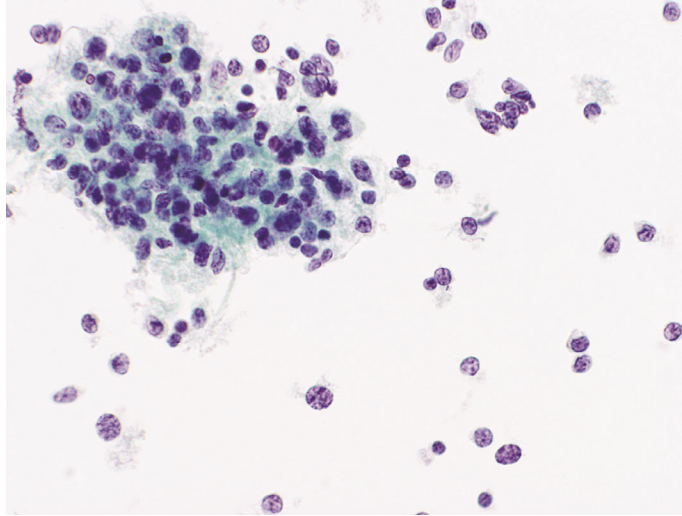


Why is Case 7 AUS?

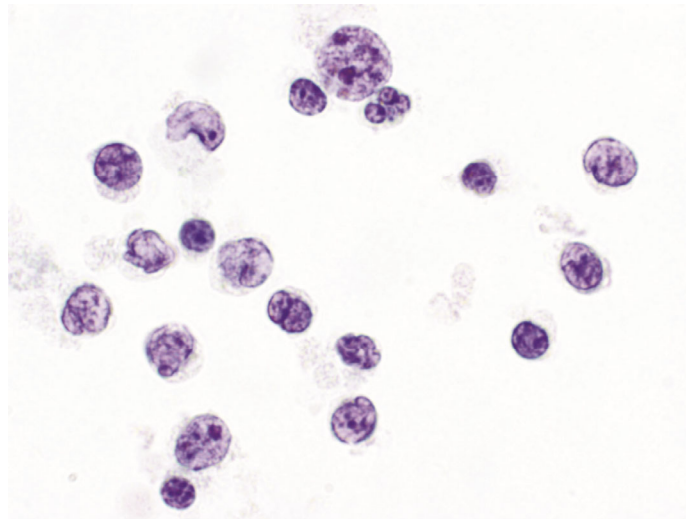
Focal nuclear atypia is one of the criteria for a dx of AUS.



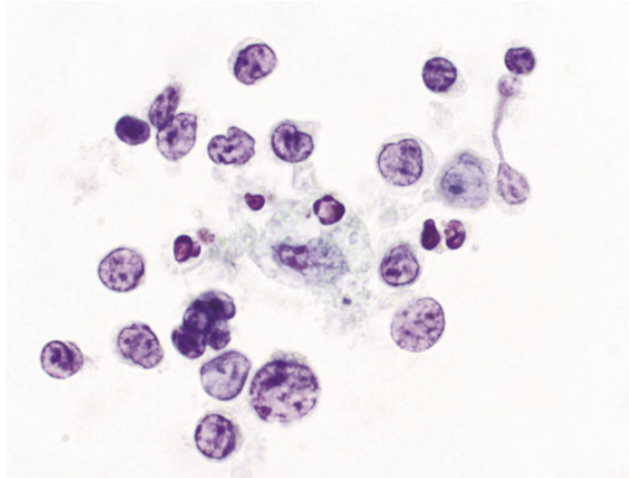
Case 8: 78 yo woman with two nodules:
4 cm enlarging right nodule and 2 cm isthmus nodule.



Case 8: 78 yo woman with two nodules:
4 cm enlarging right nodule and 2cm isthmus nodule.



Case 8: 78 yo woman with two nodules:
4 cm enlarging right nodule and 2cm isthmus nodule.



Case 8: 78 yo woman with two nodules:
4 cm enlarging right nodule and 2cm isthmus nodule.

What is your diagnosis?

- A. NONDIAGNOSTIC
- B. BENIGN, c/w Hashimoto thyroiditis
- C. AUS: atypical lymphoid cells
- D. SUSPICIOUS FOR LYMPHOMA

Case 8: 78 yo woman with two nodules:
4 cm enlarging right nodule and 2cm isthmus nodule.

What is your diagnosis?

- A. NONDIAGNOSTIC
- B. BENIGN, c/w Hashimoto thyroiditis
- C. AUS: atypical lymphoid cells
- D. SUSPICIOUS FOR LYMPHOMA

Case 8: 78 yo woman with two nodules:
4 cm enlarging right nodule and 2cm isthmus nodule.

Our diagnosis:

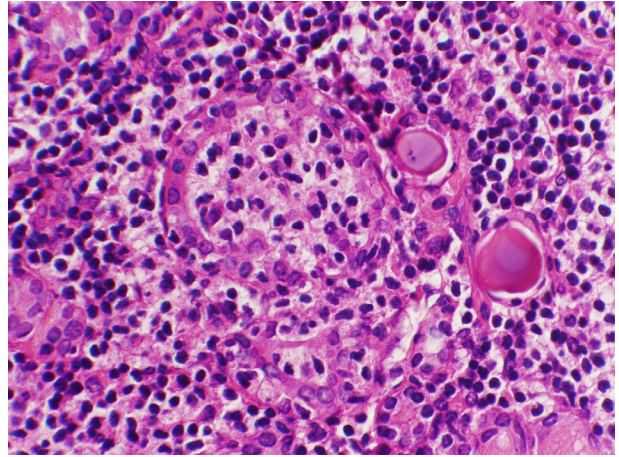
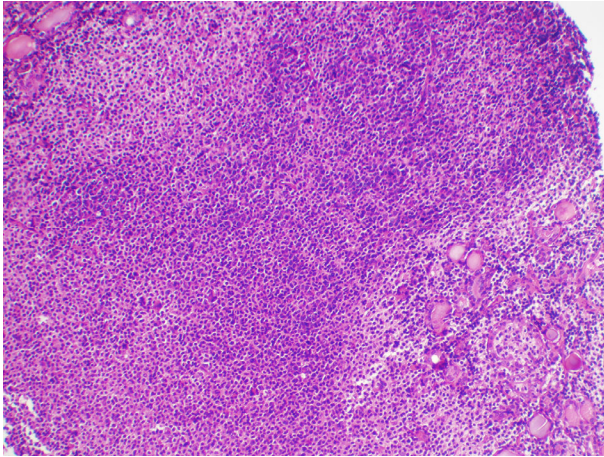
ATYPIA OF UNDETERMINED SIGNIFICANCE.

Atypical lymphoid cells, cannot rule out lymphoma.

NOTE: Additional sampling recommended for
immunophenotyping.

Case 8 follow-up:

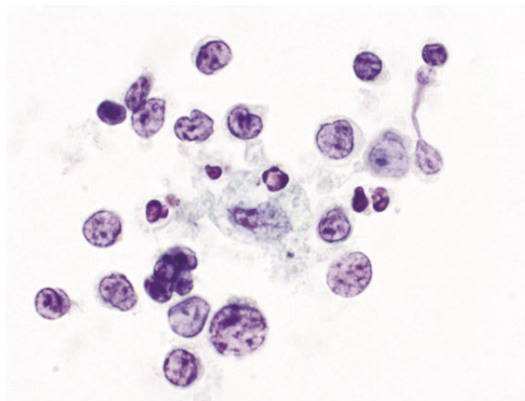
Thyroid mass biopsy one month later showed NON-HODGKIN LYMPHOMA,
EXTRA-NODAL MARGINAL ZONE TYPE



lymphoepithelial lesion

Why is Case 8 AUS?

AUS is appropriate for an atypical lymphoid infiltrate for which a repeat aspirate for flow cytometry is desirable and the degree of atypia is insufficient for “suspicious for malignancy.”



The Atypical Thyroid FNA: Summary

- 8 cases
 - 5 “real” AUS cases:
 - architectural atypia
 - nuclear and architectural atypia obscured by blood
 - all oncocytes in a patient with Hashimoto thyroiditis
 - focal nuclear atypia
 - cannot r/o lymphoma
 - 3 benign cases
 - cyst lining cells
 - focal oncocytic metaplasia
 - spherules

