

Can't-Miss ECG Cases for Hospitalists

Sanjay Divakaran, M.D.

Director, Cardiac Sarcoidosis Program
Associate Director, Nuclear Cardiology
Brigham and Women's Hospital

Assistant Professor of Medicine
Harvard Medical School

Disclosures

- None

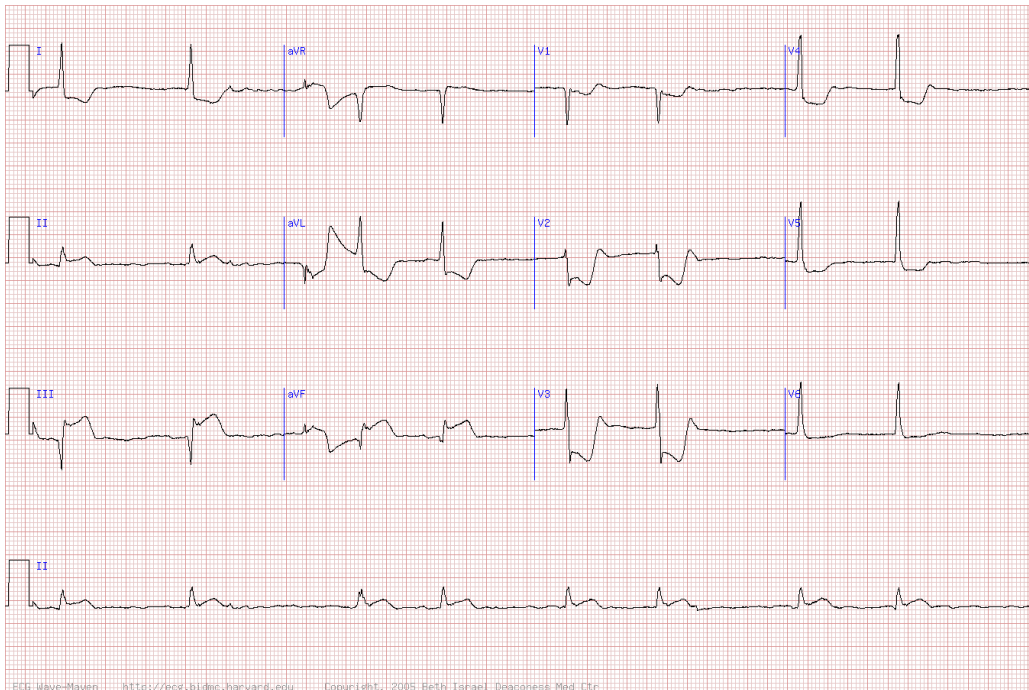
Case 1

A 67-year-old woman with a history of CAD s/p CABG presents after the development of acute chest pressure and lightheadedness. On presentation to the emergency room, her HR is 50 bpm and her blood pressure is 84/57 mmHg. Her extremities are cool. An ECG is obtained. What is the most important finding?

1. Anterior Non-ST-elevation MI
2. Anterior ST-elevation MI
3. Inferior ST-elevation MI
4. Inferior-Posterior ST-elevation MI



3



4

Nathanson LA et al. <http://ecg.bidmc.harvard.edu>.

Case 1

A 67-year-old woman with a history of CAD s/p CABG presents after the development of acute chest pressure and lightheadedness. On presentation to the emergency room, her HR is 50 bpm and her blood pressure is 84/57 mmHg. Her extremities are cool. An ECG is obtained. What is the most important finding?

1. Anterior Non-ST-elevation MI
2. Anterior ST-elevation MI
3. Inferior ST-elevation MI
4. Inferior-Posterior ST-elevation MI

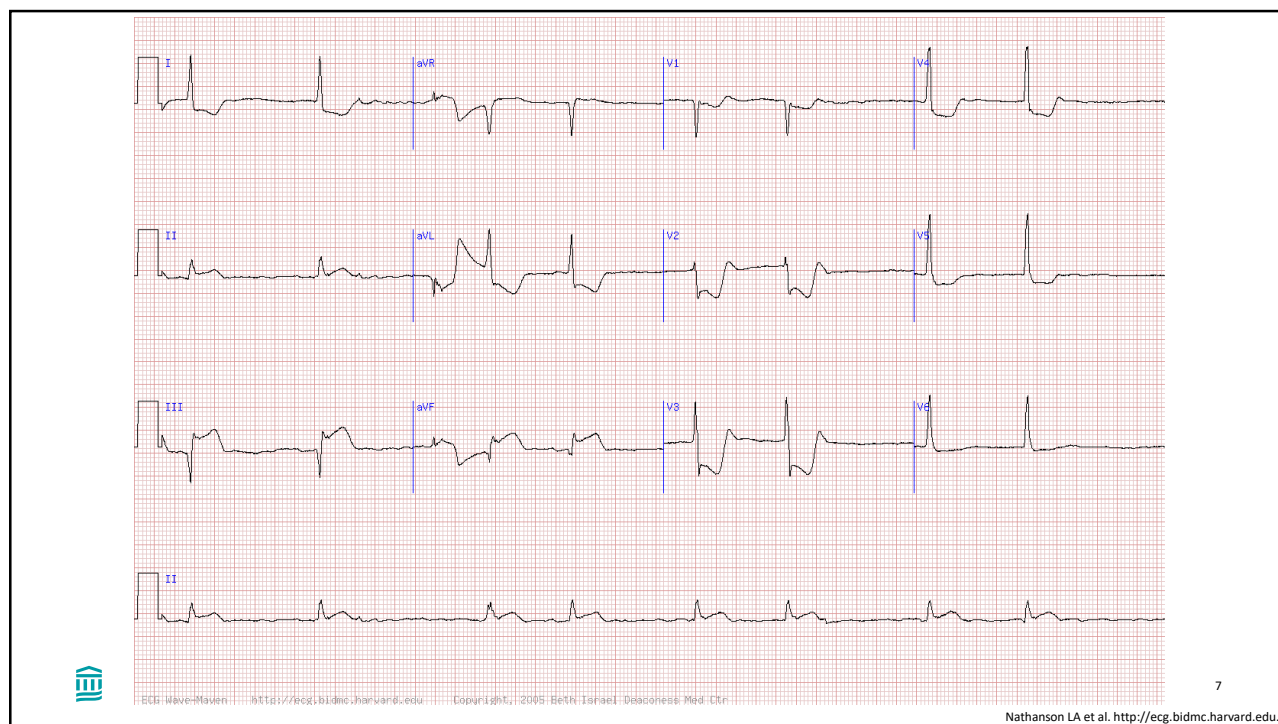


Case 1

A 67-year-old woman with a history of CAD s/p CABG presents after the development of acute chest pressure and lightheadedness. On presentation to the emergency room, her HR is 50 bpm and her blood pressure is 84/57 mmHg. Her extremities are cool. An ECG is obtained. What is the most important finding?

1. Anterior Non-ST-elevation MI
2. Anterior ST-elevation MI
3. Inferior ST-elevation MI
4. **Inferior-Posterior ST-elevation MI**





7

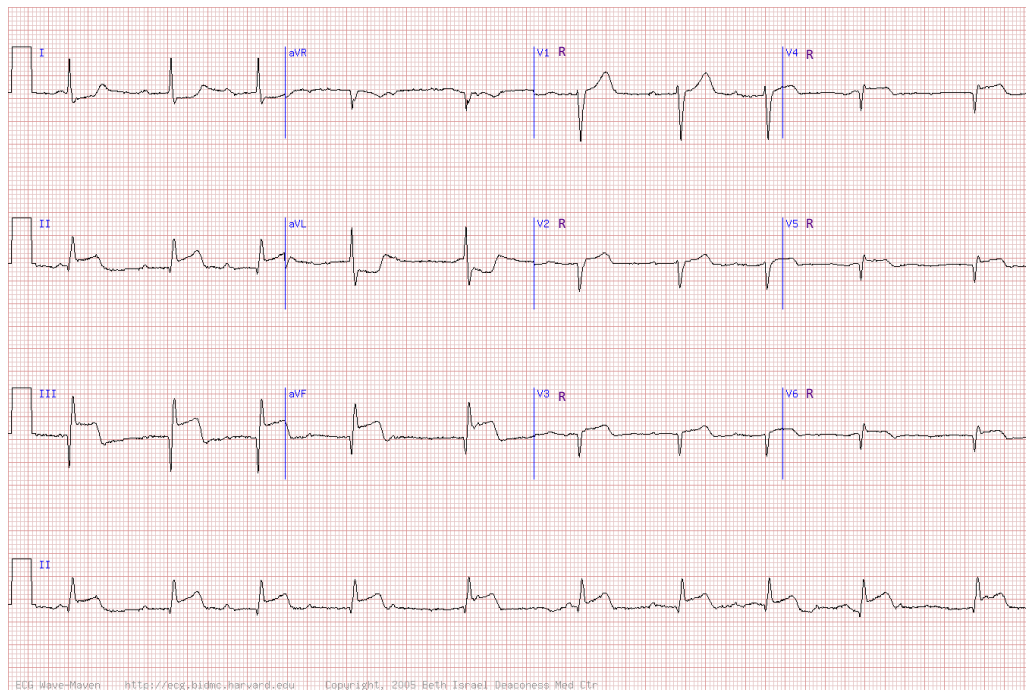
Case 2

A 60-year-old female presents with nausea, epigastric discomfort, and chest pressure that started about 45 minutes ago. An ECG is obtained. Administering which of the following medications should be avoided in the emergency room?

1. Aspirin
2. Heparin
3. Morphine
4. Nitroglycerin



8



ECG Wave-Maven <http://ecg.bidmc.harvard.edu> Copyright © 2005 Beth Israel Deaconess Med Ctr

9

Nathanson LA et al. <http://ecg.bidmc.harvard.edu>.

Case 2

A 60-year-old female presents with nausea, epigastric discomfort, and chest pressure that started about 45 minutes ago. An ECG is obtained. Administering which of the following medications should be avoided in the emergency room?

1. Aspirin
2. Heparin
3. Morphine
4. Nitroglycerin



10

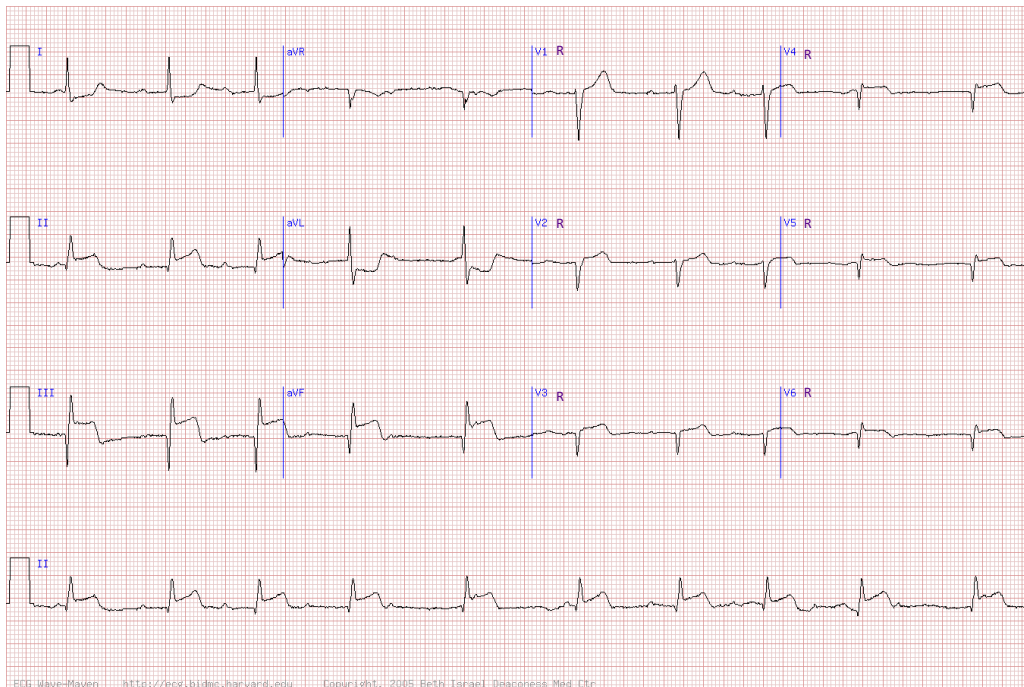
Case 2

A 60-year-old female presents with nausea, epigastric discomfort, and chest pressure that started about 45 minutes ago. An ECG is obtained. Administering which of the following medications should be avoided in the emergency room?

1. Aspirin
2. Heparin
3. Morphine
4. **Nitroglycerin**



11



12

Nathanson LA et al. <http://ecg.bidmc.harvard.edu>.

TABLE I Association Between Location of Culprit Lesion and Presence of ST-Segment Ratio in Leads III and II of >1 and ST-Segment Elevation in V_1

Culprit Lesion (n)	ST III $>$ II (n) (%)	ST Elevated in V_1 + ST III $>$ II	RV AMI
Proximal RCA (19)	17 (89%)	5	6
Mid RCA (25)	20 (80%)	0	4
Distal RCA (8)	1 (12.5%)	0	0
Left circumflex (17)	0	0	0

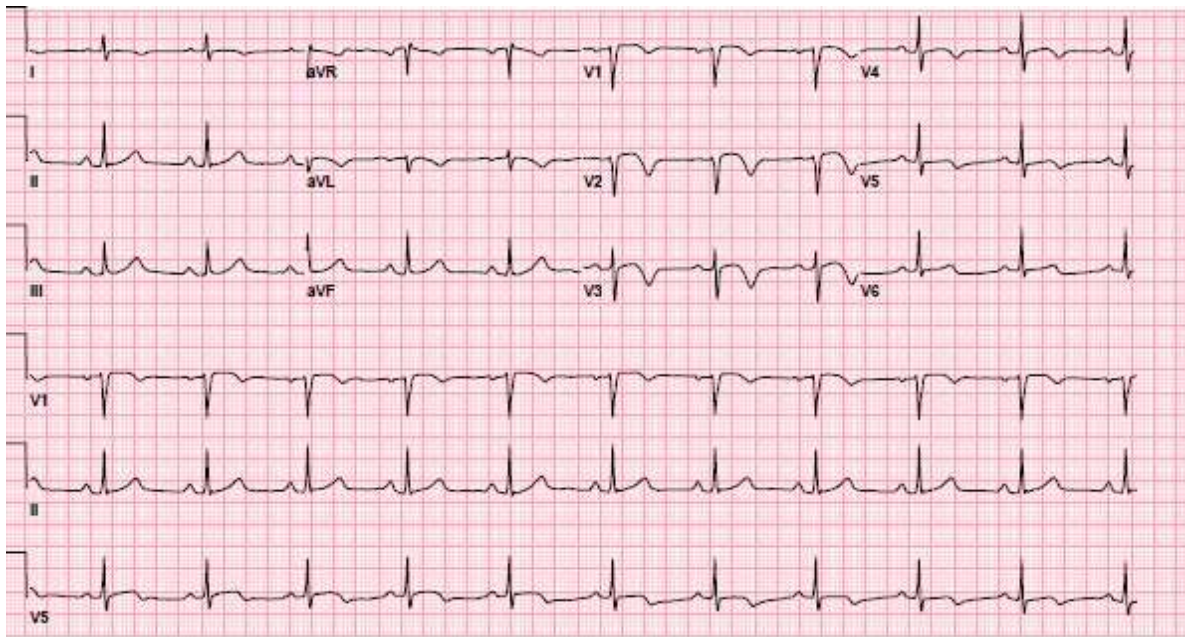


Case 3

A 71-year-old man with a history of hypertension, dyslipidemia, and former tobacco use presents to the emergency department with two weeks of chest pressure associated with exertion. He has never had these symptoms before. He currently has no chest pressure. An ECG is obtained. His exam is unremarkable and high-sensitivity troponin (hs-Tn) is < 6 ng/dL. After evaluation, a decision is made to perform coronary angiography. Which of the following would you expect to see?

1. Non-obstructive coronary artery disease
2. Proximal right coronary artery stenosis
3. Proximal left anterior descending artery stenosis
4. Proximal left circumflex coronary artery stenosis





15

Regan E. StatPearls Publishing LLC. 2019.

Case 3

A 71-year-old man with a history of hypertension, dyslipidemia, and former tobacco use presents to the emergency department with two weeks of chest pressure associated with exertion. He has never had these symptoms before. He currently has no chest pressure. An ECG is obtained. His exam is unremarkable and high-sensitivity troponin (hs-Tn) is < 6 ng/dL. After evaluation, a decision is made to perform coronary angiography. Which of the following would you expect to see?

1. Non-obstructive coronary artery disease
2. Proximal right coronary artery stenosis
3. Proximal left anterior descending artery stenosis
4. Proximal left circumflex coronary artery stenosis



16

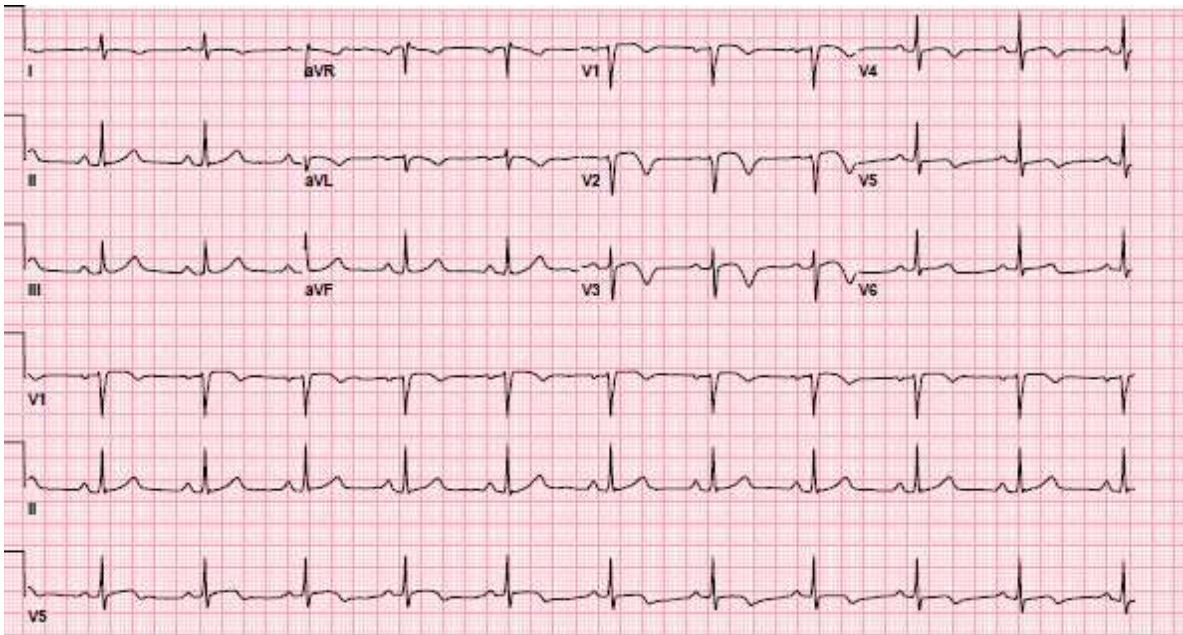
Case 3

A 71-year-old man with a history of hypertension, dyslipidemia, and former tobacco use presents to the emergency department with two weeks of chest pressure associated with exertion. He has never had these symptoms before. He currently has no chest pressure. An ECG is obtained. His exam is unremarkable and high-sensitivity troponin (hs-Tn) is < 6 ng/dL. After evaluation, a decision is made to perform coronary angiography. Which of the following would you expect to see?

1. Non-obstructive coronary artery disease
2. Proximal right coronary artery stenosis
3. **Proximal left anterior descending artery stenosis**
4. Proximal left circumflex coronary artery stenosis



17



18

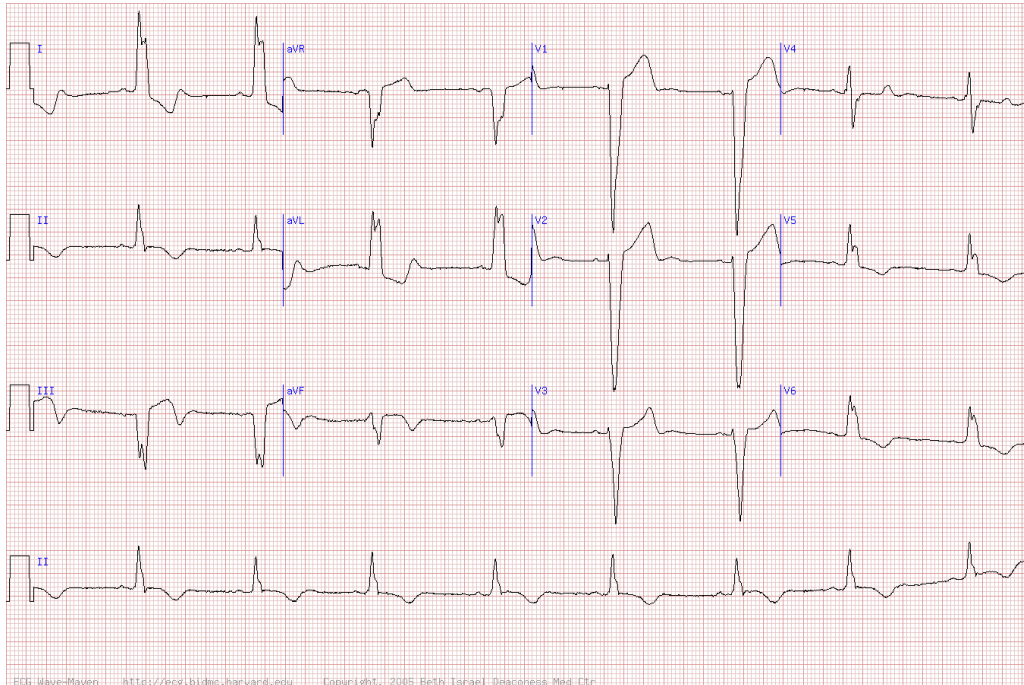
Case 4

An 82-year-old female with hypertension, diabetes, and known left bundle branch block is brought into the emergency room by her daughter due shortness of breath at rest. An ECG is obtained. Which myocardial territory is abnormal on this ECG?

1. Anterior
2. Posterior
3. Inferior
4. Lateral



19



20

Nathanson LA et al. <http://ecg.bidmc.harvard.edu>.

Case 4

An 82-year-old female with hypertension, diabetes, and known left bundle branch block is brought into the emergency room by her daughter due shortness of breath at rest. An ECG is obtained. Which myocardial territory is abnormal on this ECG?

1. Anterior
2. Posterior
3. Inferior
4. Lateral

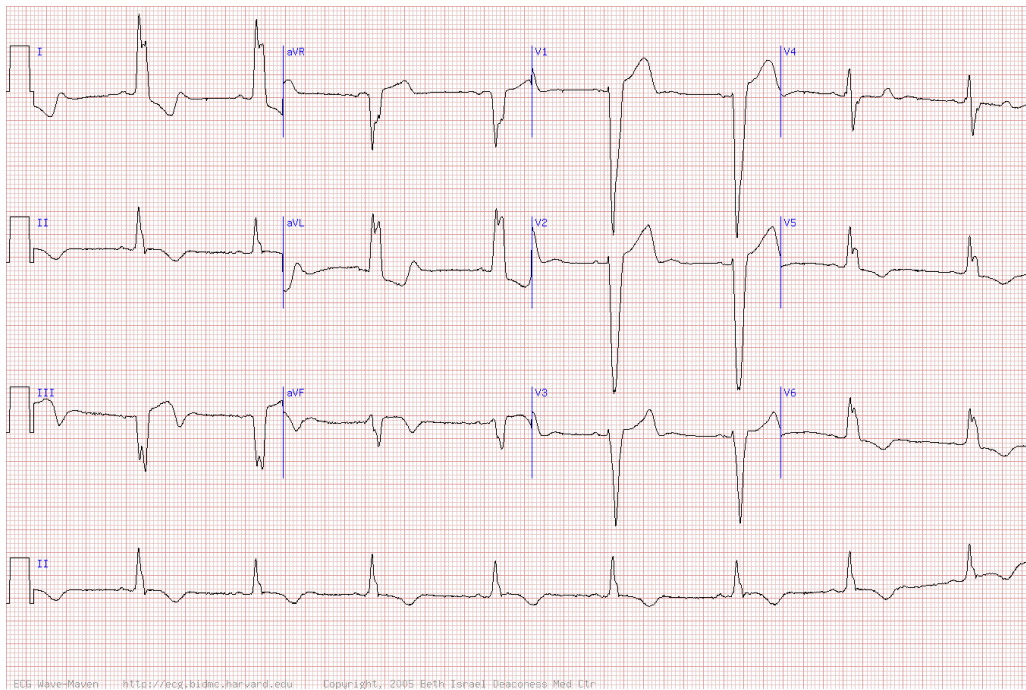


Case 4

An 82-year-old female with hypertension, diabetes, and known left bundle branch block is brought into the emergency room by her daughter due shortness of breath at rest. An ECG is obtained. Which myocardial territory is abnormal on this ECG?

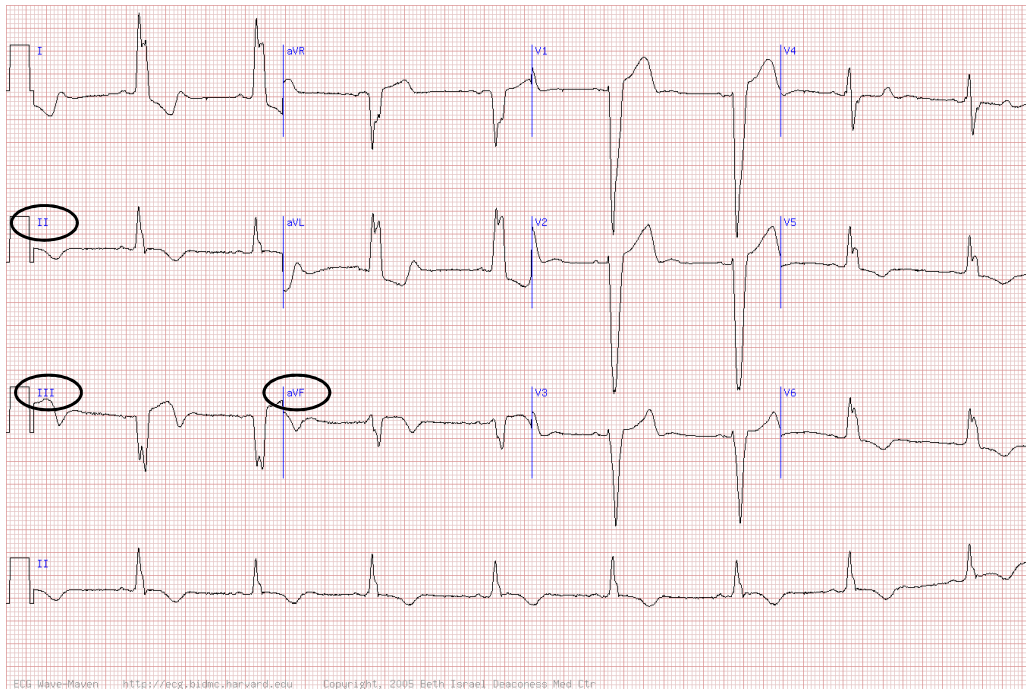
1. Anterior
2. Posterior
3. **Inferior**
4. Lateral





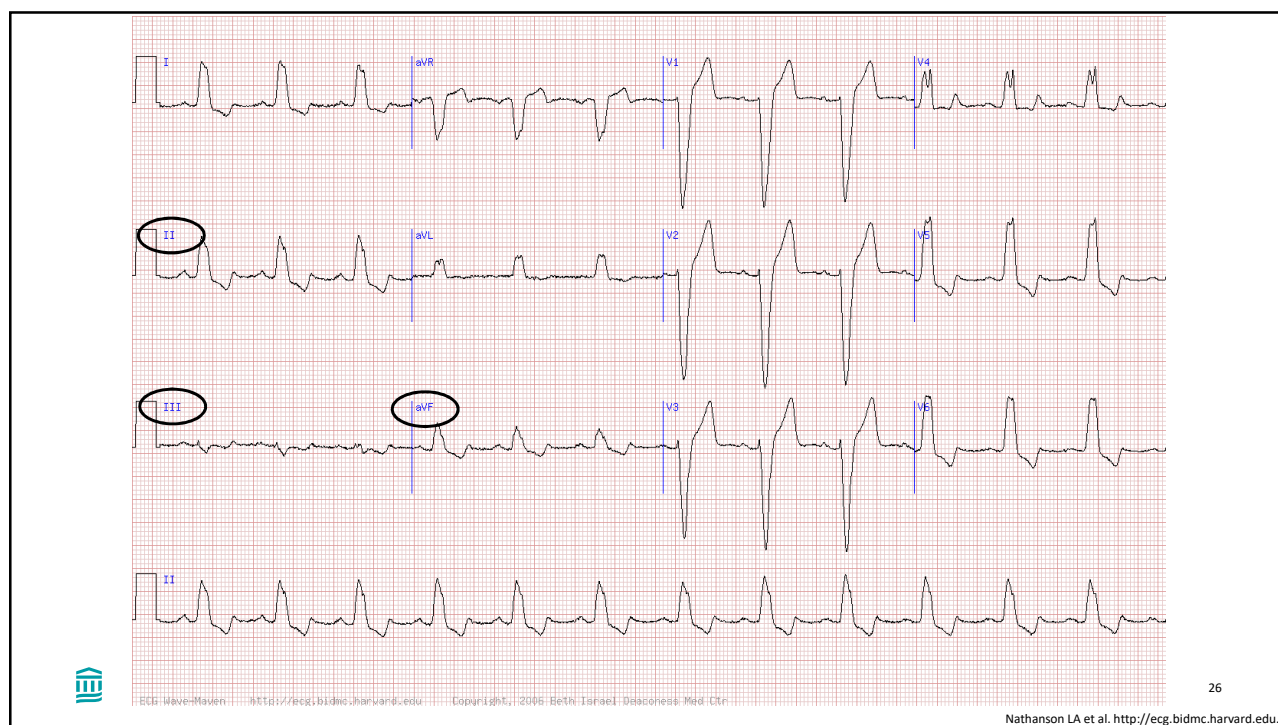
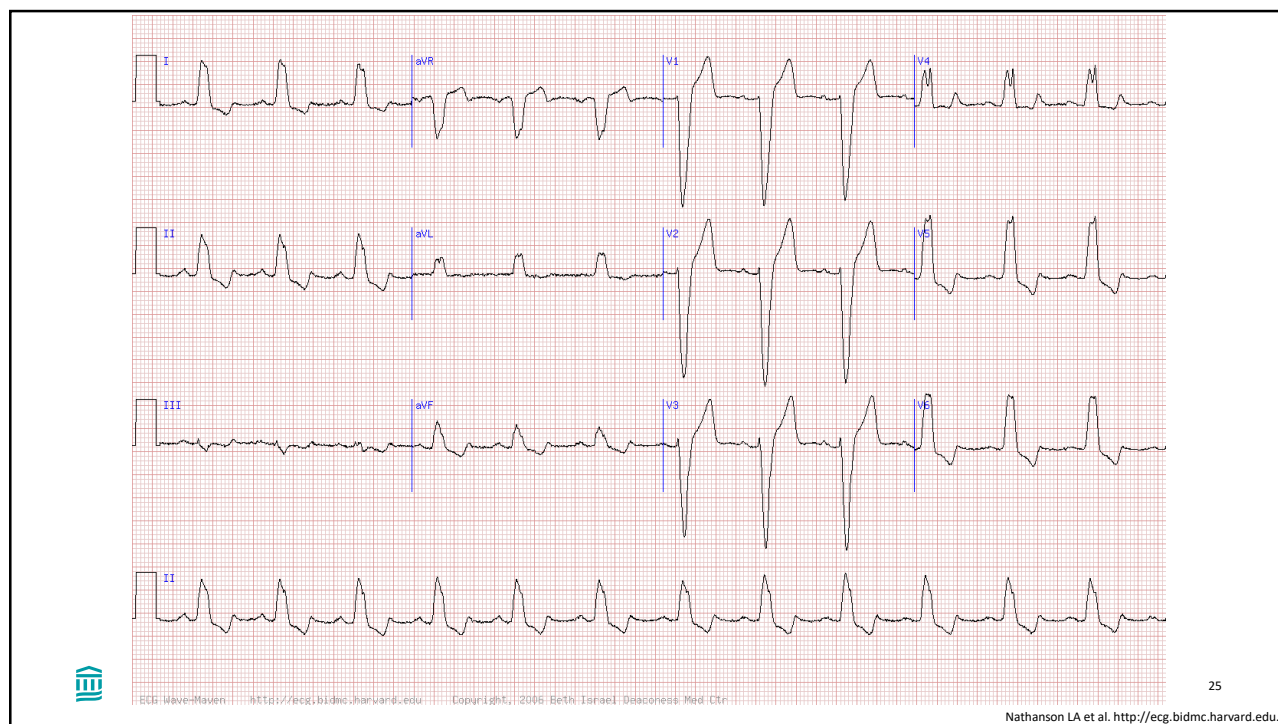
23

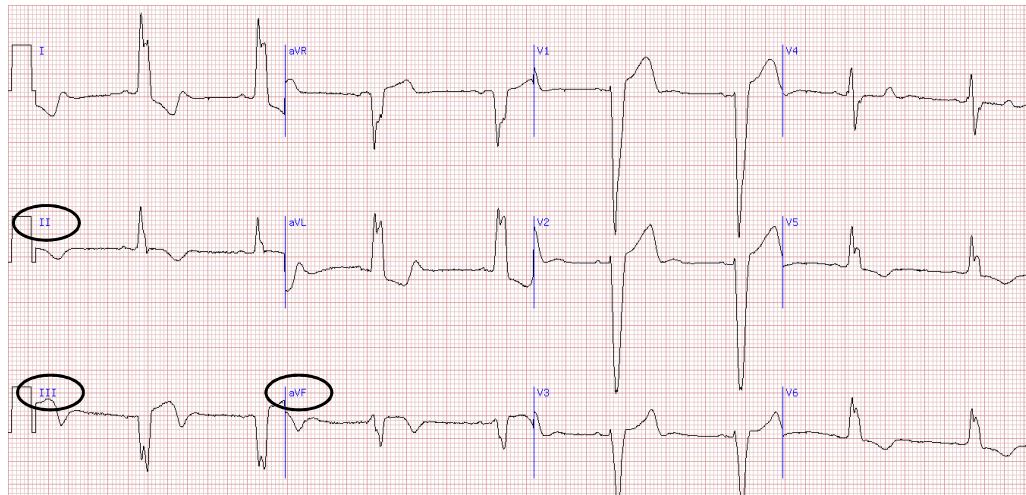
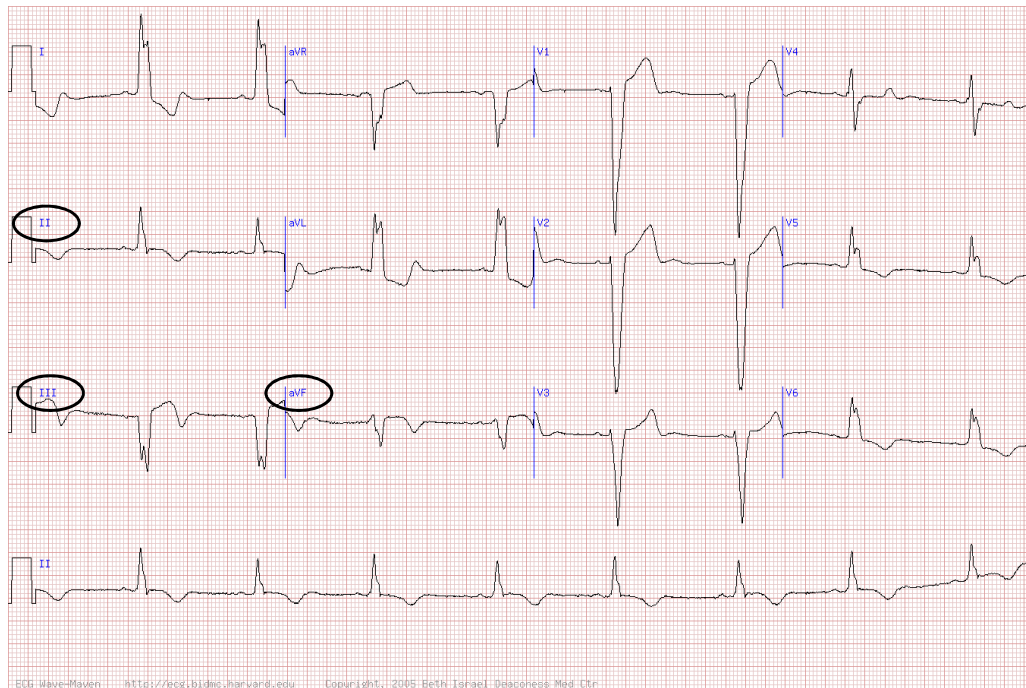
Nathanson LA et al. <http://ecg.bidmc.harvard.edu>.



24

Nathanson LA et al. <http://ecg.bidmc.harvard.edu>.





ST-T waves are typically opposite in direction to the major vector of the QRS in uncomplicated bundle branch blocks



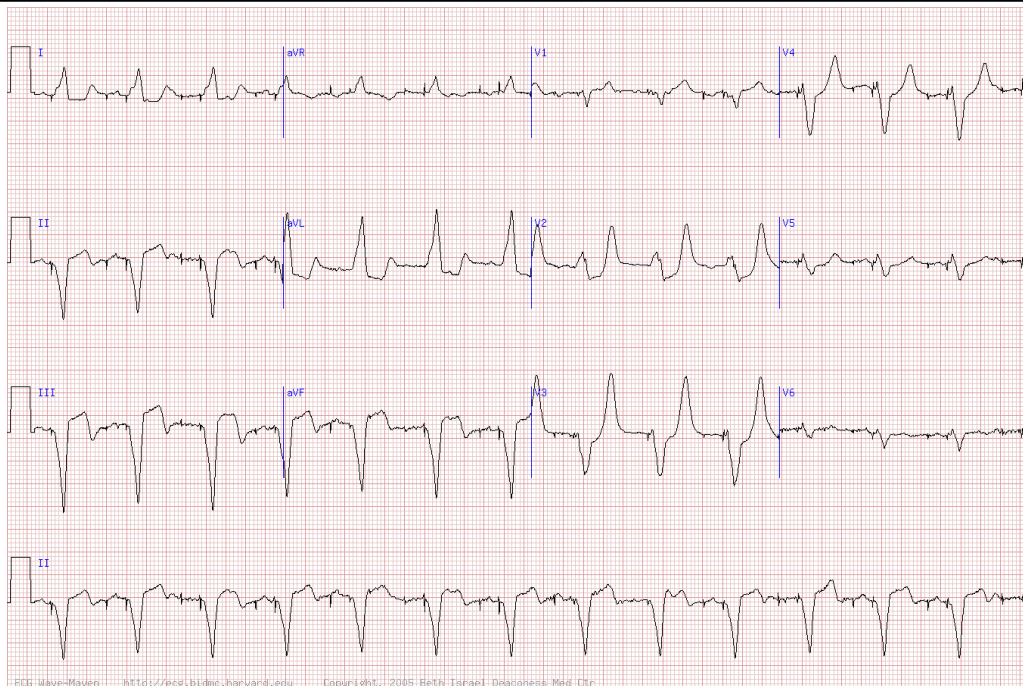
Case 5

An 80-year-old female with a history of pacemaker placement due to sick sinus syndrome and Mobitz Type II secondary degree heart block presents with dizziness, lightheadedness, and nausea approximately 90 minutes in duration. An ECG is obtained. What is the most likely cause of her symptoms?

1. Myocardial infarction
2. Atrial lead malfunction
3. Ventricular lead malfunction
4. Pericardial effusion



29



ECG WaveMaster ... <http://ecg.bidmc.harvard.edu> ... Copyright © 2005 Beth Israel Deaconess Med Ctr

30

Nathanson LA et al. <http://ecg.bidmc.harvard.edu>.

Case 5

An 80-year-old female with a history of pacemaker placement due to sick sinus syndrome and Mobitz Type II secondary degree heart block presents with dizziness, lightheadedness, and nausea approximately 90 minutes in duration. An ECG is obtained. What is the most likely cause of her symptoms?

1. Myocardial infarction
2. Atrial lead malfunction
3. Ventricular lead malfunction
4. Pericardial effusion

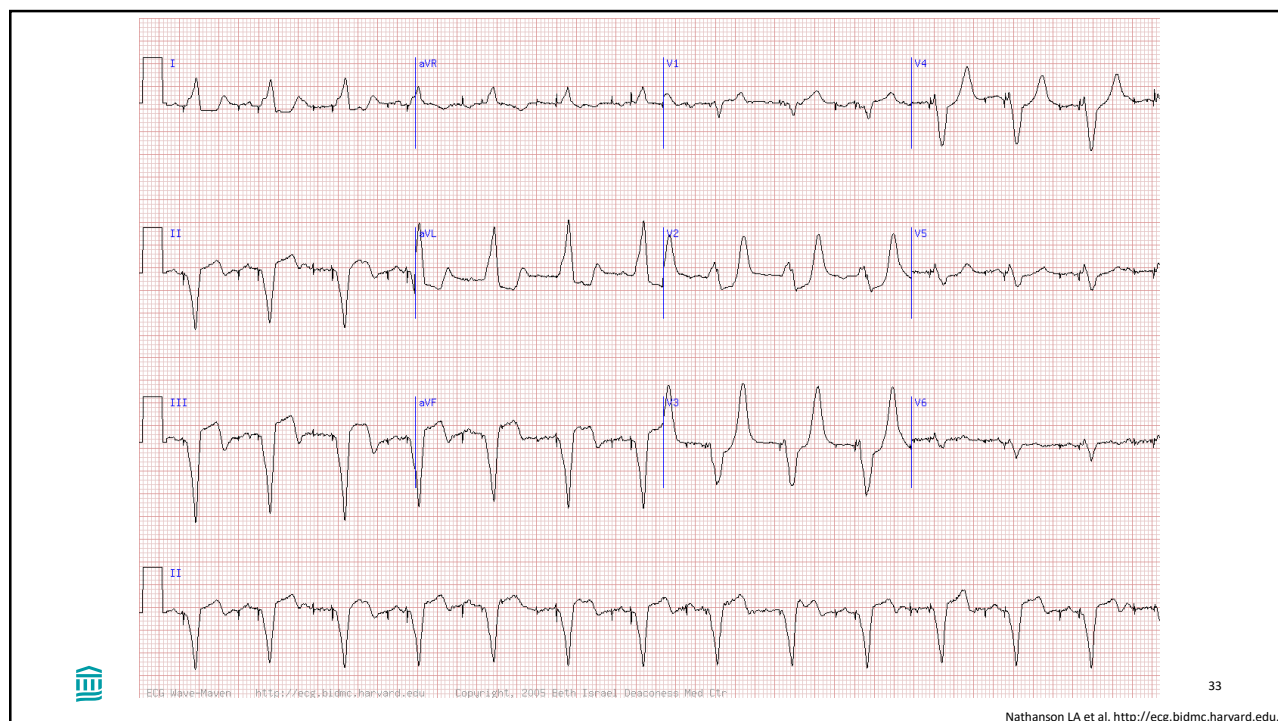


Case 5

An 80-year-old female with a history of pacemaker placement due to sick sinus syndrome and Mobitz Type II secondary degree heart block presents with dizziness, lightheadedness, and nausea approximately 90 minutes in duration. An ECG is obtained. What is the most likely cause of her symptoms?

1. **Myocardial infarction**
2. Atrial lead malfunction
3. Ventricular lead malfunction
4. Pericardial effusion





3 ECG criteria with independent value in diagnosis of acute MI in the presence of LBBB

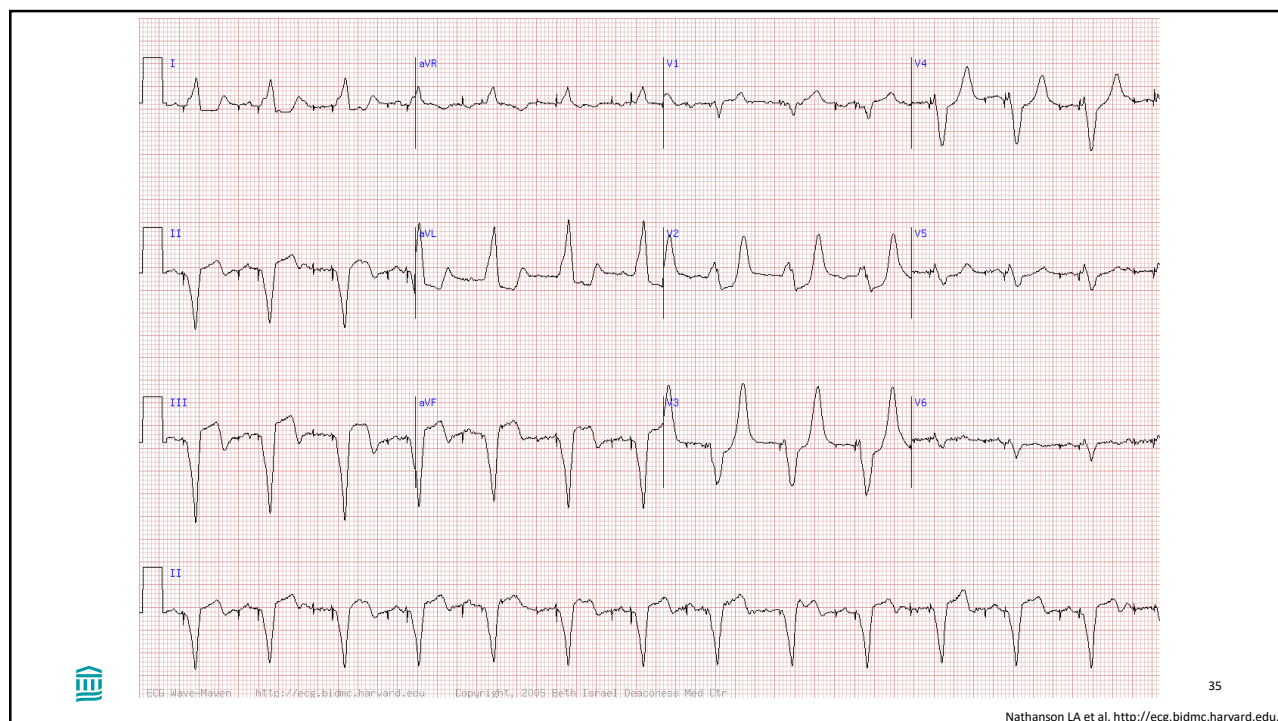
- ST segment elevation of 1mm or more that is in the same direction (concordant) as the QRS complex in any lead
- ST segment depression of 1 mm or more in any lead from V1 to V3
- ST segment elevation of 5 mm or more that is discordant with the QRS complex

Early Electrocardiographic Diagnosis of Acute Myocardial Infarction in the Presence of Ventricular Paced Rhythm

Elena B. Sgarbossa, MD, Sergio L. Pinski, MD, Kathy B. Gates, and Galen S. Wagner, MD, for the GUSTO-I Investigators

34

Sgarbossa EB et al. Am J Cardiol. 1996 Feb 15;77(5):423-4.



3 ECG criteria with independent value in diagnosis of acute MI in the presence of LBBB

- ST segment elevation of 1mm or more that is in the same direction (concordant) as the QRS complex in any lead
- ST segment depression of 1 mm or more in any lead from V1 to V3
- **ST segment elevation of 5 mm or more that is discordant with the QRS complex**

Early Electrocardiographic Diagnosis of Acute Myocardial Infarction in the Presence of Ventricular Paced Rhythm

Elena B. Sgarbossa, MD, Sergio L. Pinski, MD, Kathy B. Gates, and Galen S. Wagner, MD, for the GUSTO-I Investigators

36

Sgarbossa EB et al. Am J Cardiol. 1996 Feb 15;77(5):423-4.

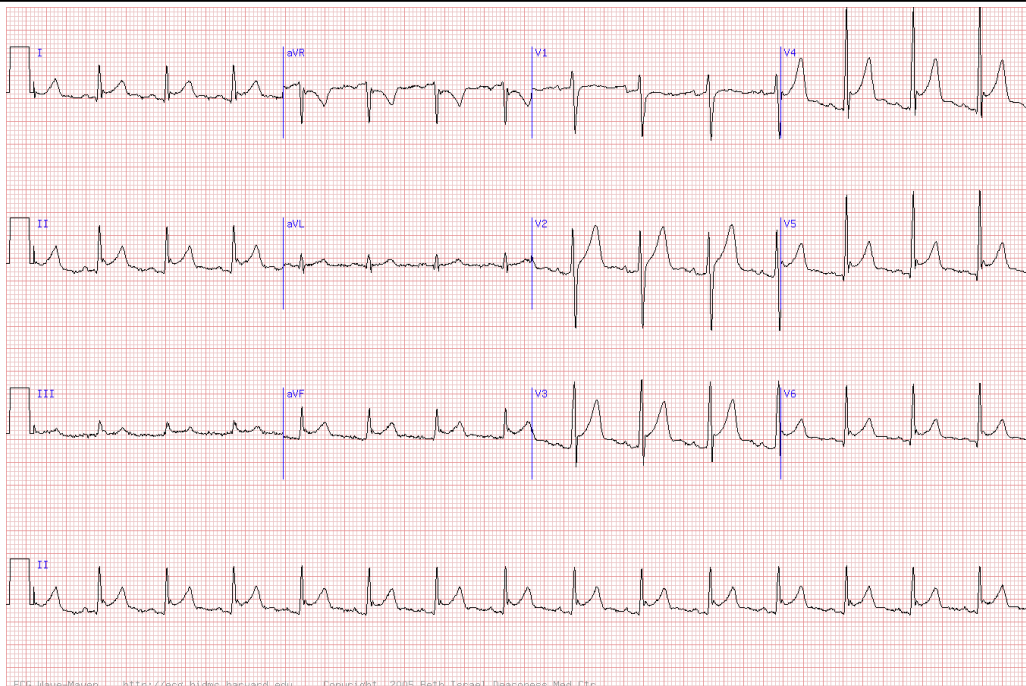
Case 6

This ECG is most consistent with which of the following clinical scenarios?

1. A 54-year-old man with a history of diabetes with crushing, central chest pressure acute in onset
2. A 72-year-old woman with a history of hypertension and dyslipidemia with acute onset epigastric pain and diaphoresis
3. A 32-year-old man with a history of morbid obesity with asymmetric leg swelling and shortness of breath two days after abdominal surgery
4. A 44-year-old woman with a history of hypertension with positional, pleuritic chest discomfort



37



ECG-Wave-Maven <http://ecg.bidmc.harvard.edu> Copyright © 2015 Beth Israel Deaconess Medical Center

38

Nathanson LA et al. <http://ecg.bidmc.harvard.edu>.

Case 6

This ECG is most consistent with which of the following clinical scenarios?

1. A 54-year-old man with a history of diabetes with crushing, central chest pressure acute in onset
2. A 72-year-old woman with a history of hypertension and dyslipidemia with acute onset epigastric pain and diaphoresis
3. A 32-year-old man with a history of morbid obesity with asymmetric leg swelling and shortness of breath two days after abdominal surgery
4. A 44-year-old woman with a history of hypertension with positional, pleuritic chest discomfort



39

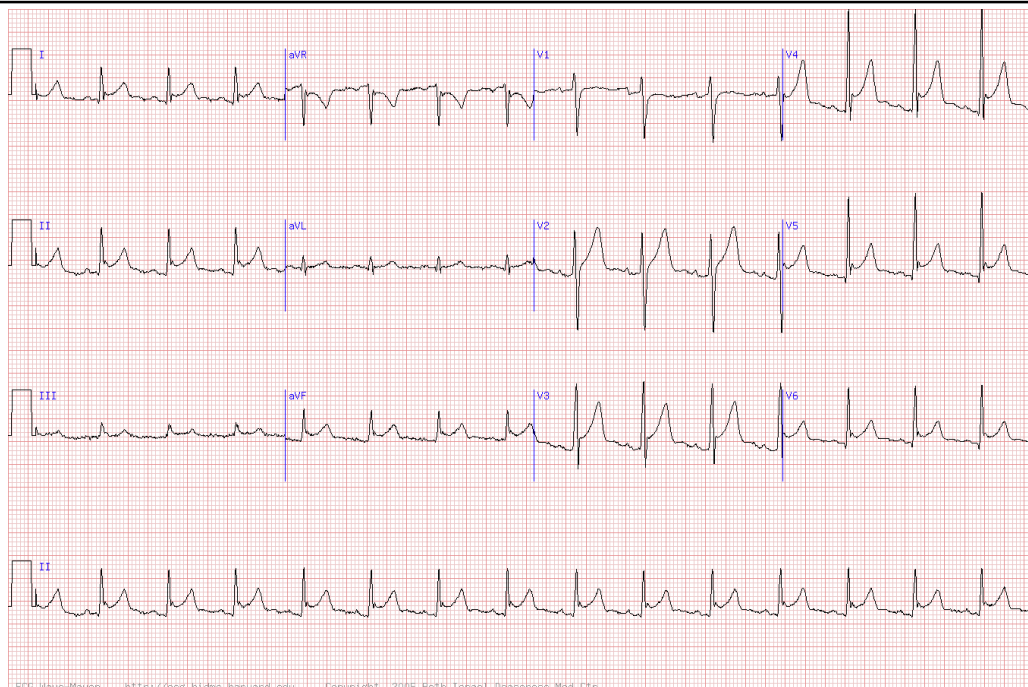
Case 6

This ECG is most consistent with which of the following clinical scenarios?

1. A 54-year-old man with a history of diabetes with crushing, central chest pressure acute in onset
2. A 72-year-old woman with a history of hypertension and dyslipidemia with acute onset epigastric pain and diaphoresis
3. A 32-year-old man with a history of morbid obesity with asymmetric leg swelling and shortness of breath two days after abdominal surgery
4. **A 44-year-old woman with a history of hypertension with positional, pleuritic chest discomfort**



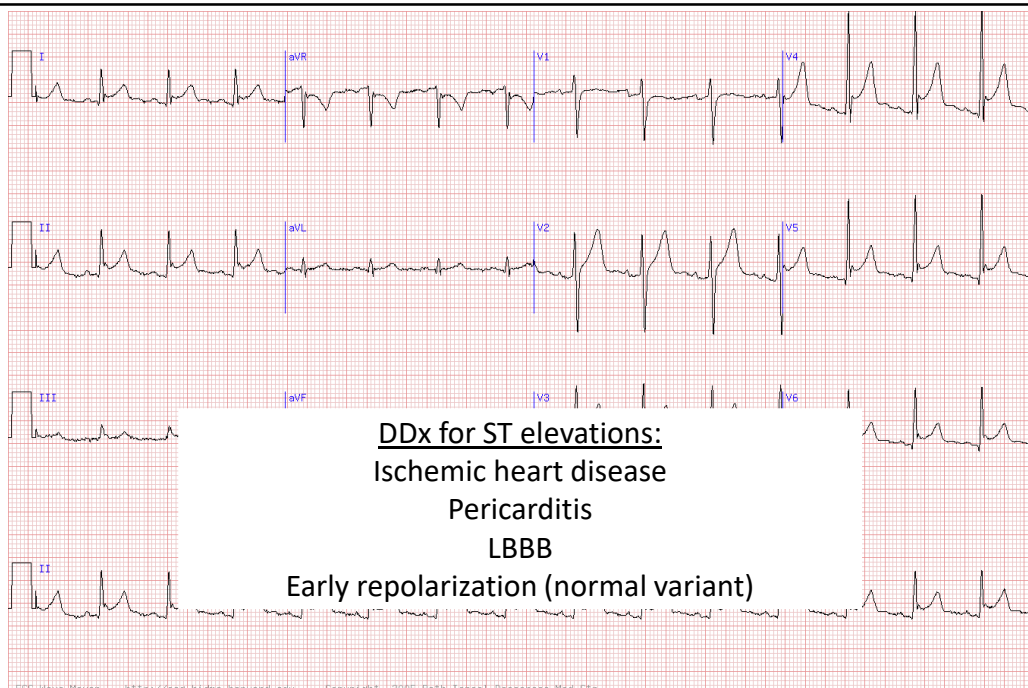
40



ECG Wave-Maven <http://ecg.bidmc.harvard.edu> Copyright, 2005 Beth Israel Deaconess Med Ctr

41

Nathanson LA et al. <http://ecg.bidmc.harvard.edu>.



ECG Wave-Maven <http://ecg.bidmc.harvard.edu> Copyright, 2005 Beth Israel Deaconess Med Ctr

42

Nathanson LA et al. <http://ecg.bidmc.harvard.edu>.

DDx for ST elevations:

Ischemic heart disease

Pericarditis

LBBB

Early repolarization (normal variant)

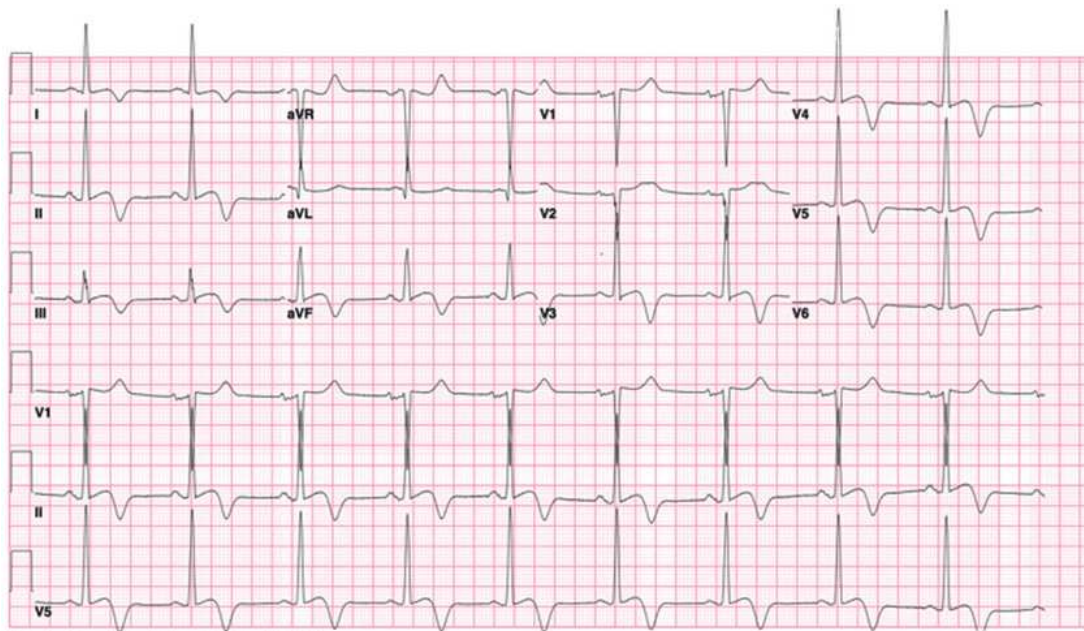
Case 7

A 58-year-old female with a history of hypertension presents to her primary care physician's office for peri-operative risk assessment before a total knee replacement. She has no cardiovascular symptoms. An ECG is obtained. Which of the following is the most likely cause of this patient's ECG abnormalities?

1. Prior myocardial infarction
2. Current ischemia
3. Hypertrophic cardiomyopathy
4. Prior myocarditis



43



25mm/s 10mm/mV 150Hz 8.0 SP2 CID: 65535

44

Abugroun A et al. Cardiol Res. 2017;8(5):265-268.

Case 7

A 58-year-old female with a history of hypertension presents to her primary care physician's office for peri-operative risk assessment before a total knee replacement. She has no cardiovascular symptoms. An ECG is obtained. Which of the following is the most likely cause of this patient's ECG abnormalities?

1. Prior myocardial infarction
2. Current ischemia
3. Hypertrophic cardiomyopathy
4. Prior myocarditis

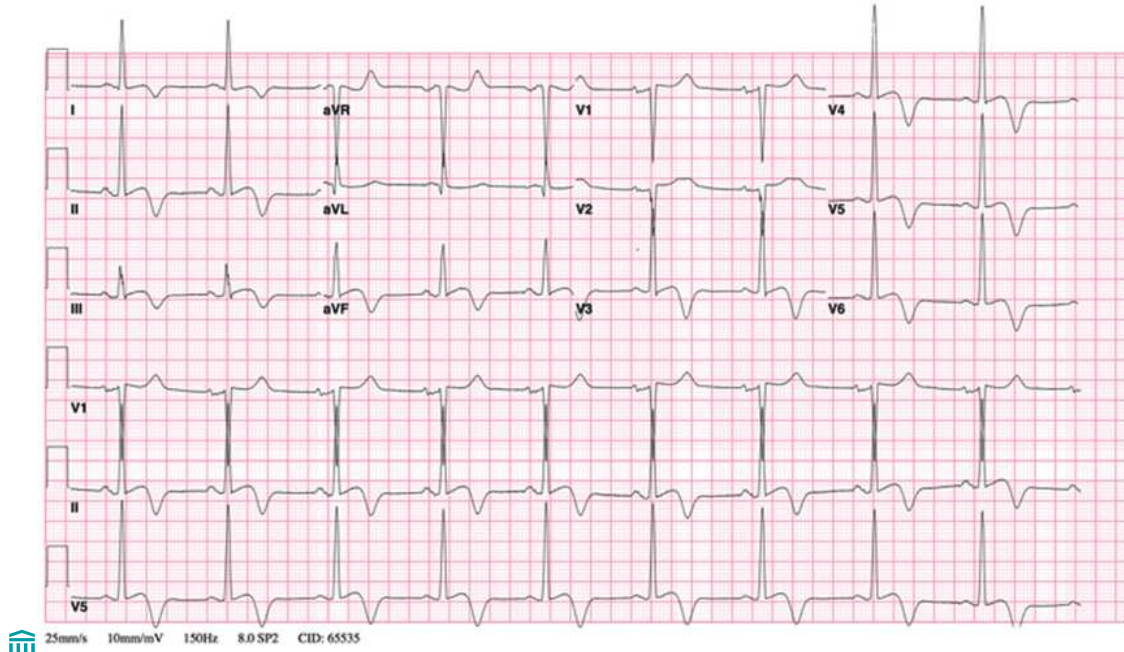


Case 7

A 58-year-old female with a history of hypertension presents to her primary care physician's office for peri-operative risk assessment before a total knee replacement. She has no cardiovascular symptoms. An ECG is obtained. Which of the following is the most likely cause of this patient's ECG abnormalities?

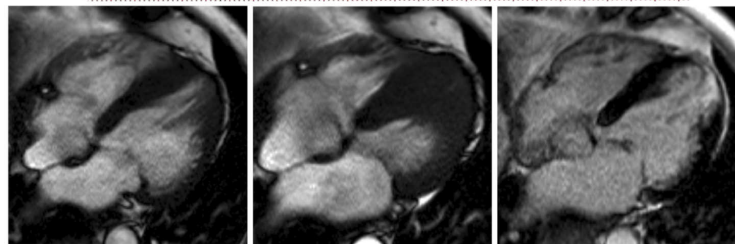
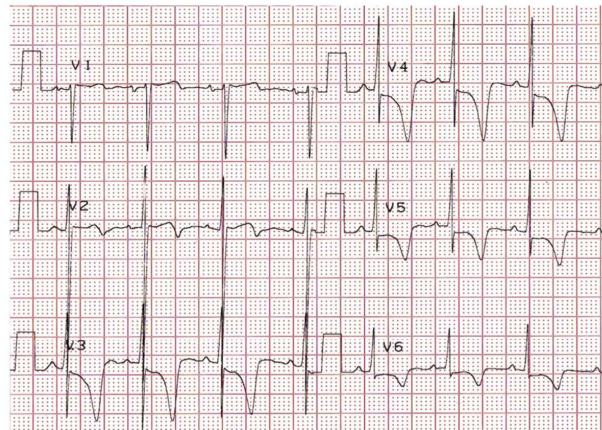
1. Prior myocardial infarction
2. Current ischemia
3. **Hypertrophic cardiomyopathy**
4. Prior myocarditis





47

Abugroun A et al. Cardiol Res. 2017;8(5):265-268.



48

Finocchiaro G et al. Heart Rhythm. 2019 August 10.



Nomenclature	Sigmoidal HCM	Reverse curve HCM	Apical HCM	Neutral HCM
Prevalence	40-50%	30-40%	10%	10%
Age group	> 50-60 years	< 50-60 years	< 50-60 years	< 50-60 years



49

Canepa M et al. Heart. 2016 Jul 15;102(14):1087-94.

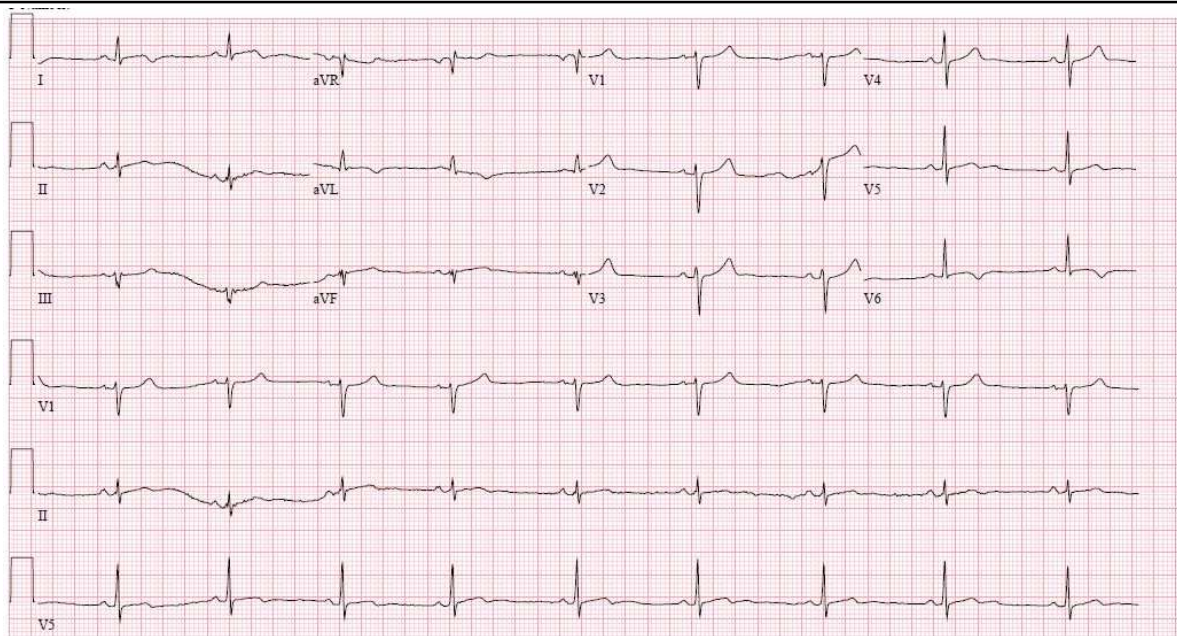
Case 8

A 39-year-old male presents to the emergency department with two weeks of intermittent chest discomfort while jogging. An ECG is obtained. Troponin-T was elevated at 0.07 ng/mL. Due to concern for a non-ST-elevation myocardial infarction, he underwent coronary angiography which revealed no obstructive coronary artery disease. Which of the following is the most likely cause of the ECG abnormalities?

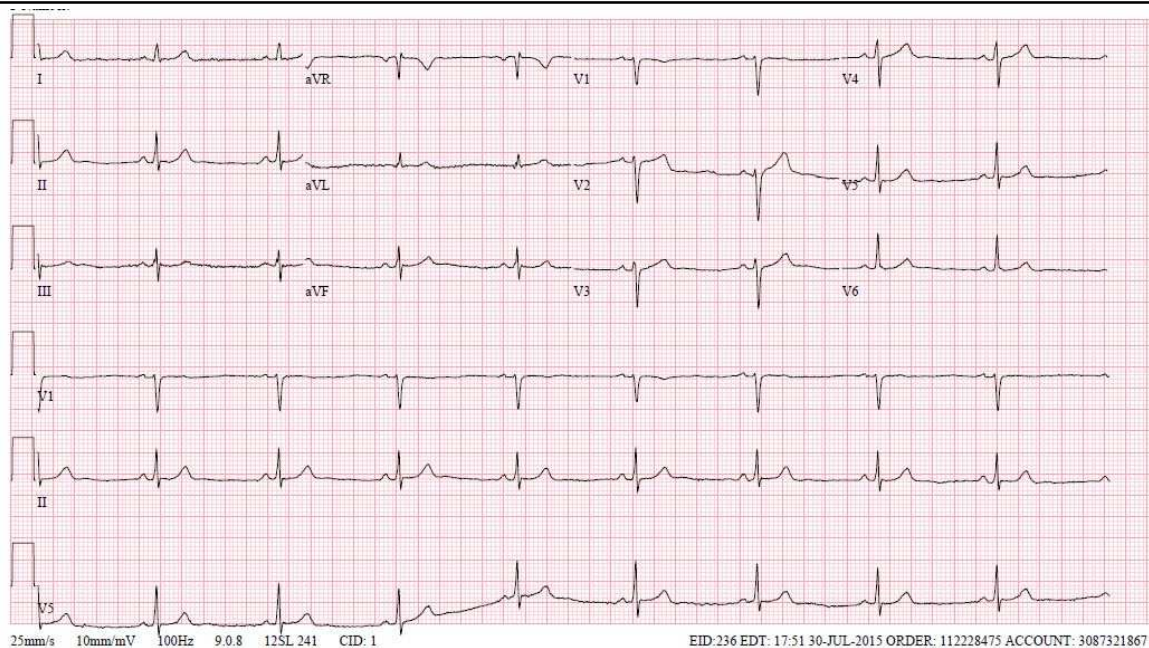
1. Myocarditis
2. Pulmonary embolism
3. Pericarditis
4. Left ventricular hypertrophy and associated strain pattern



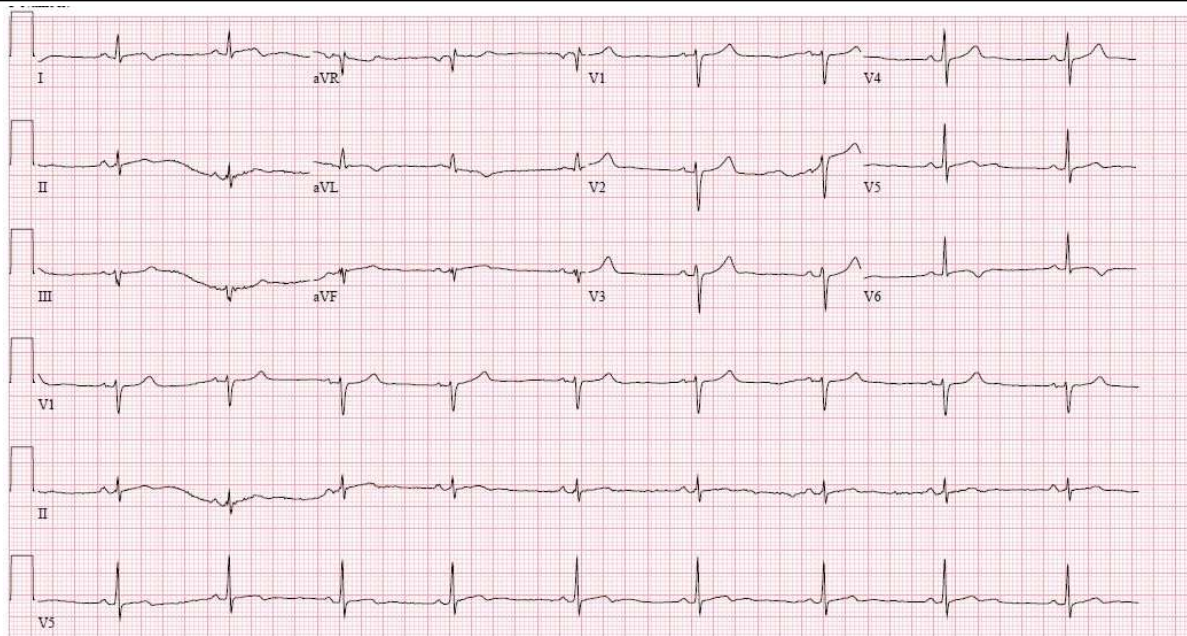
50



51



52



53

Case 8

A 39-year-old male presents to the emergency department with who two weeks of intermittent chest discomfort while jogging. An ECG is obtained. Troponin-T was elevated at 0.07 ng/mL. Due to concern for a non-ST-elevation myocardial infarction, he underwent coronary angiography which revealed no obstructive coronary artery disease. Which of the following is the most likely cause of the ECG abnormalities?

1. Myocarditis
2. Pulmonary embolism
3. Pericarditis
4. Left ventricular hypertrophy and associated strain pattern



54

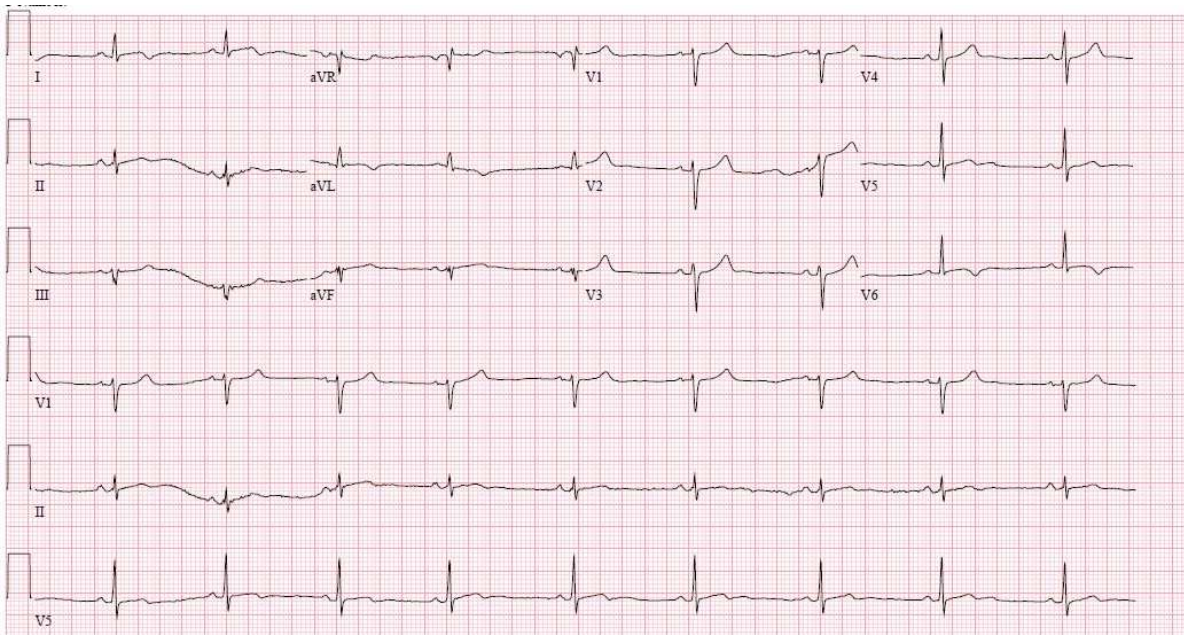
Case 8

A 39-year-old male presents to the emergency department with who two weeks of intermittent chest discomfort while jogging. An ECG is obtained. Troponin-T was elevated at 0.07 ng/mL. Due to concern for a non-ST-elevation myocardial infarction, he underwent coronary angiography which revealed no obstructive coronary artery disease. Which of the following is the most likely cause of the ECG abnormalities?

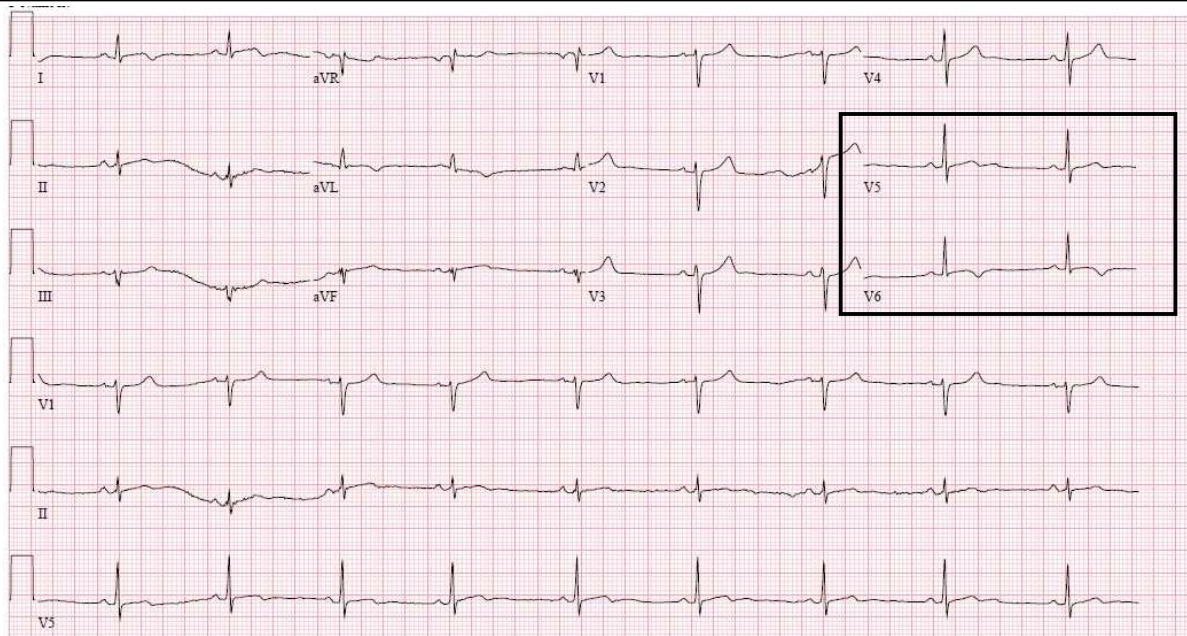
1. **Myocarditis**
2. Pulmonary embolism
3. Pericarditis
4. Left ventricular hypertrophy and associated strain pattern



55



56



57

+Troponin in the absence of overt ischemic heart disease

Type II MI

Tachyarrhythmias
Shock
HTN urgency/emergency
Cocaine use

Non-ischemic myocardial damage

Cardiac contusion
Defibrillator shocks
Myocarditis
Cardiotoxic agents

Indeterminate/ Multifactorial

Stress cardiomyopathy
Severe pulmonary embolism
Severe neurologic disease
Infiltrative cardiomyopathy
Sepsis



58

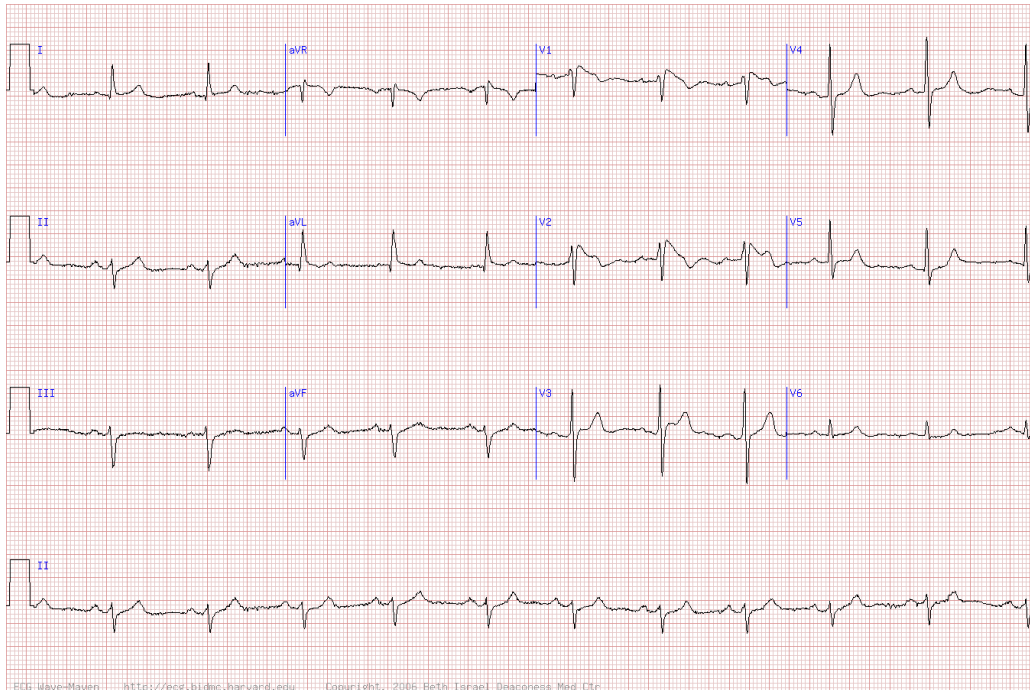
Case 9

A 61-year-old male presents to urgent care clinic due to non-exertional, sharp chest pain over the last 2-3 months. An ECG is obtained. Evidence of which of the following is present on his ECG?

1. Right bundle branch block
2. Right ventricular hypertrophy
3. Right ventricular strain
4. Brugada pattern



59



60

ECG Wave-Maven: <http://ecg.bidmc.harvard.edu> Copyright © 2016 Beth Israel Deaconess Medical Center

Nathanson LA et al. <http://ecg.bidmc.harvard.edu>.

Case 9

A 61-year-old male presents to urgent care clinic due to non-exertional, sharp chest pain over the last 2-3 months. An ECG is obtained. Evidence of which of the following is present on his ECG?

1. Right bundle branch block
2. Right ventricular hypertrophy
3. Right ventricular strain
4. Brugada pattern

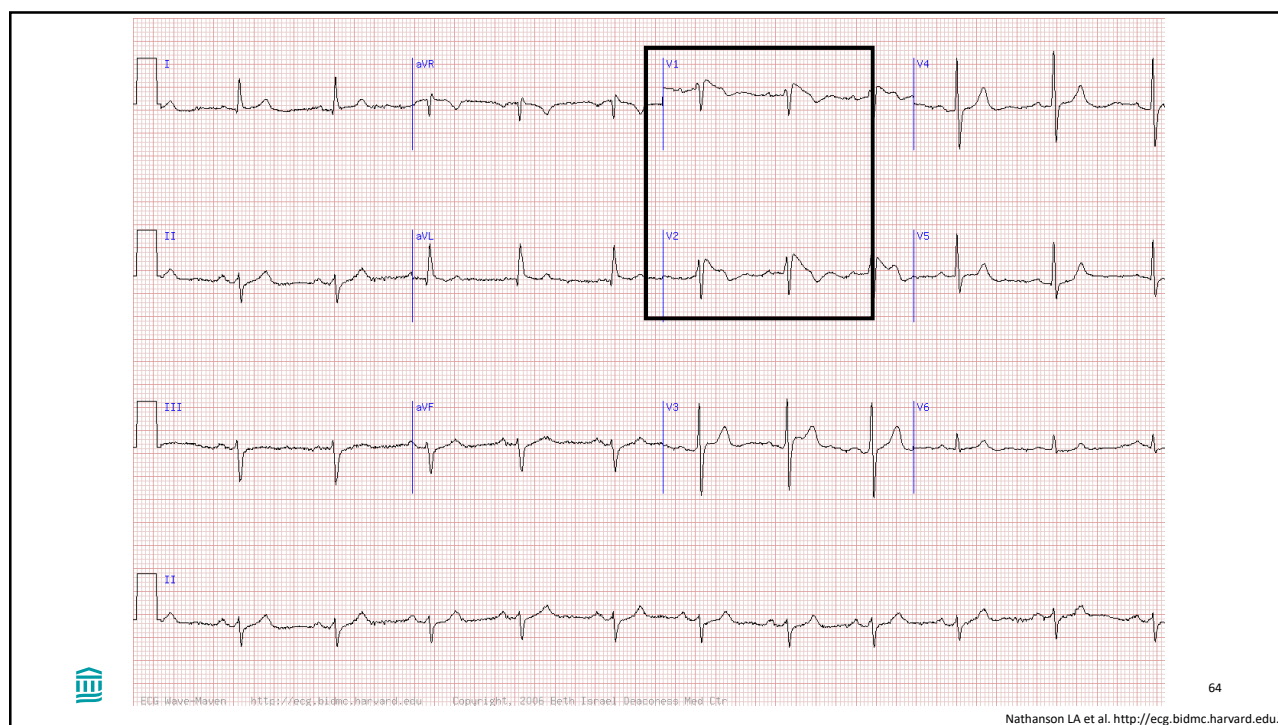
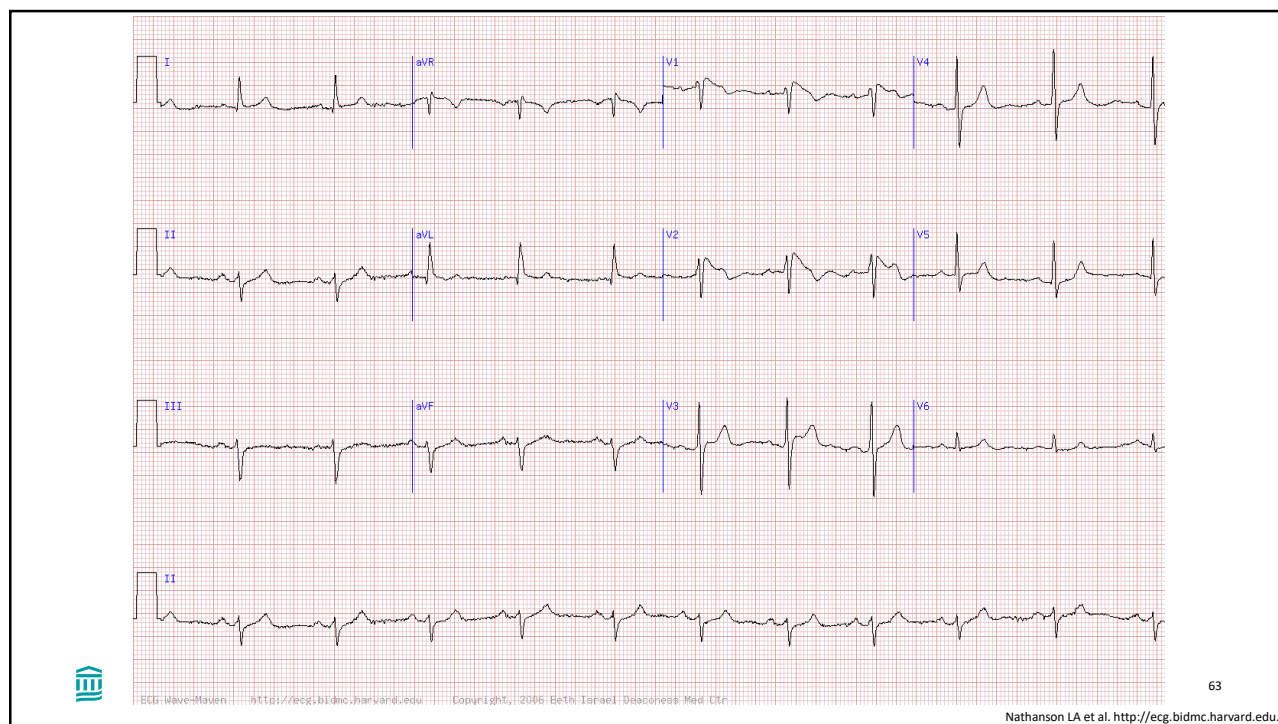


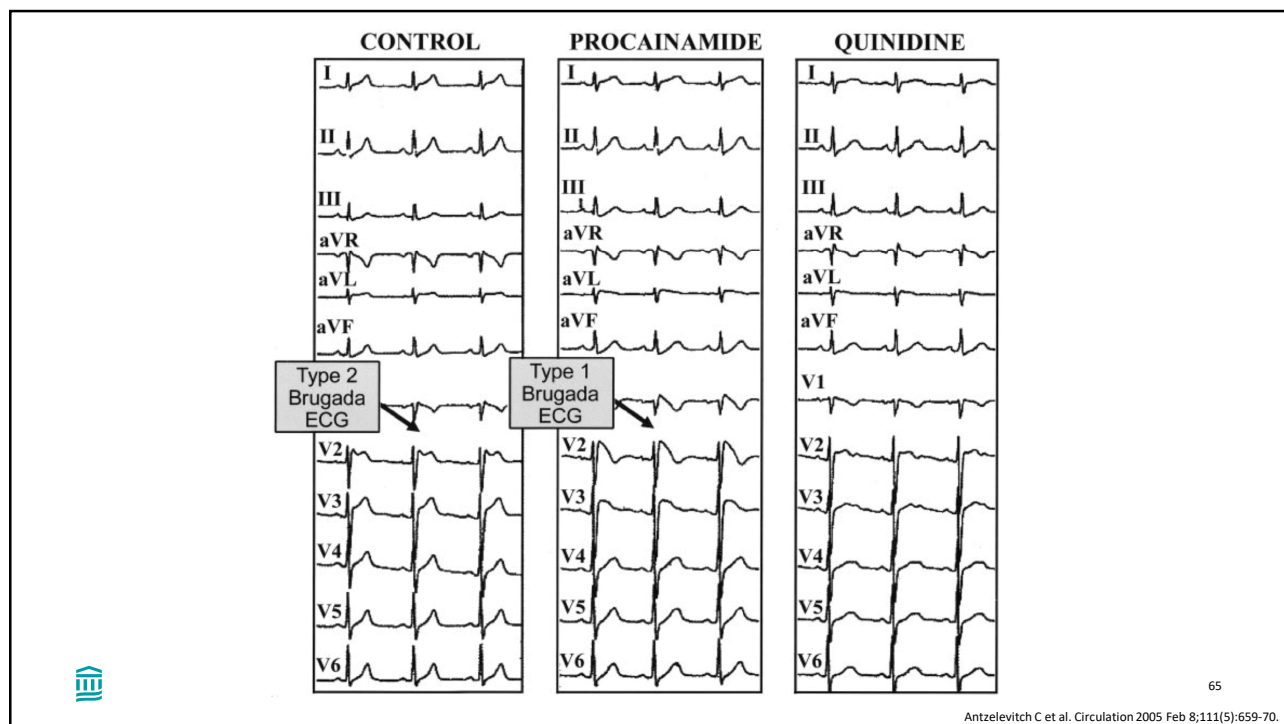
Case 9

A 61-year-old male presents to urgent care clinic due to non-exertional, sharp chest pain over the last 2-3 months. An ECG is obtained. Evidence of which of the following is present on his ECG?

1. Right bundle branch block
2. Right ventricular hypertrophy
3. Right ventricular strain
4. **Brugada pattern**







Brugada Syndrome

Associated with a high risk for sudden cardiac death

- Estimated to be responsible for at least 4% of all sudden deaths and at least 20% of sudden deaths in patients with structurally normal hearts
- Causative mutations in the SCN genes SCN5A and SCN10A (encode α subunit of the cardiac sodium channel gene)
- **Cases of suspected Brugada syndrome should have evaluation for underlying heart disease by a cardiologist and imaging**



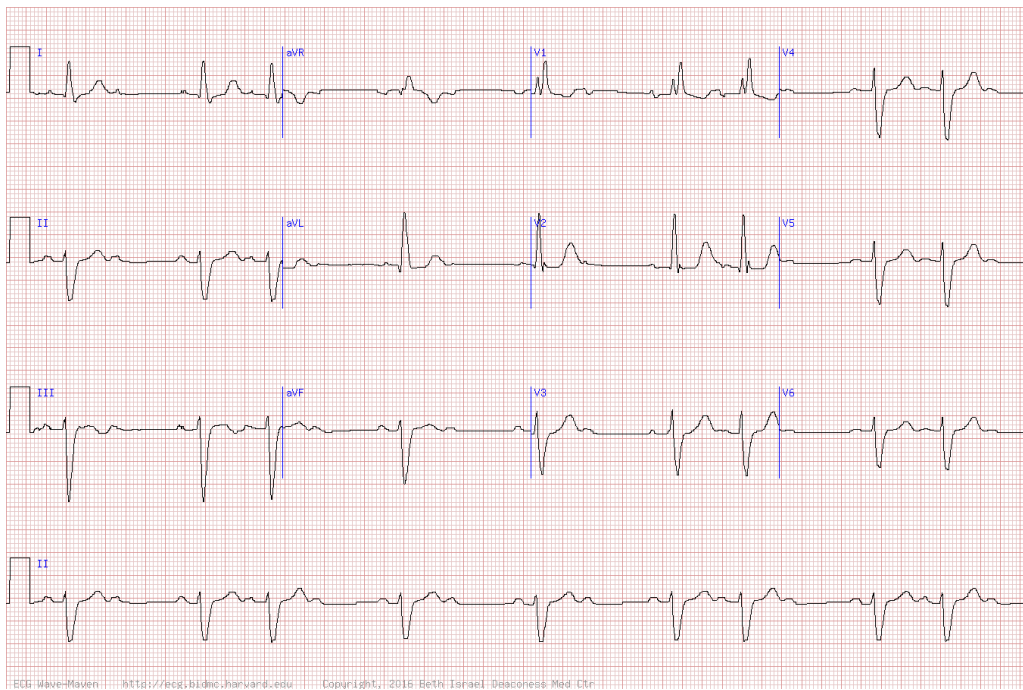
Case 10

An 80-year-old man presents to the emergency room due to recurrent episodes of dizziness and lightheadedness not associated with activity. Examination is notable for bradycardia. An ECG is obtained. Which of the following is present?

1. 1st Degree AV block
2. Mobitz Type I 2nd Degree AV Block
3. Mobitz Type II 2nd Degree AV Block
4. 3rd Degree AV Block



67



68

Nathanson LA et al. <http://ecg.bidmc.harvard.edu>.

Case 10

An 80-year-old man presents to the emergency room due to recurrent episodes of dizziness and lightheadedness not associated with activity. Examination is notable for bradycardia. An ECG is obtained. Which of the following is present?

1. 1st Degree AV block
2. Mobitz Type I 2nd Degree AV Block
3. Mobitz Type II 2nd Degree AV Block
4. 3rd Degree AV Block

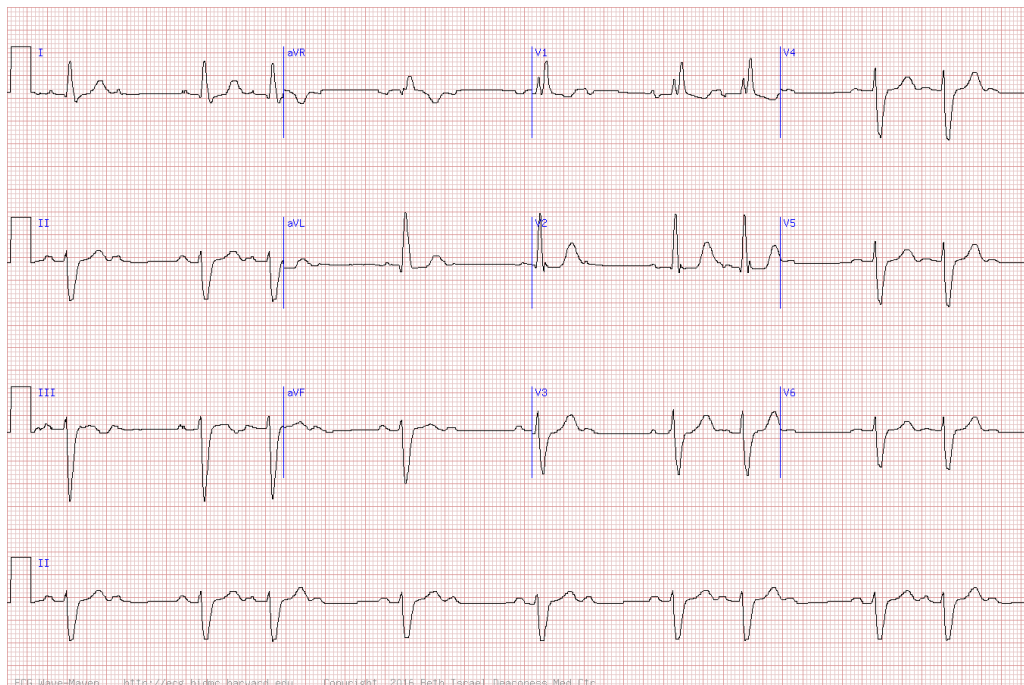


Case 10

An 80-year-old man presents to the emergency room due to recurrent episodes of dizziness and lightheadedness not associated with activity. Examination is notable for bradycardia. An ECG is obtained. Which of the following is present?

1. 1st Degree AV block
2. Mobitz Type I 2nd Degree AV Block
3. **Mobitz Type II 2nd Degree AV Block**
4. 3rd Degree AV Block

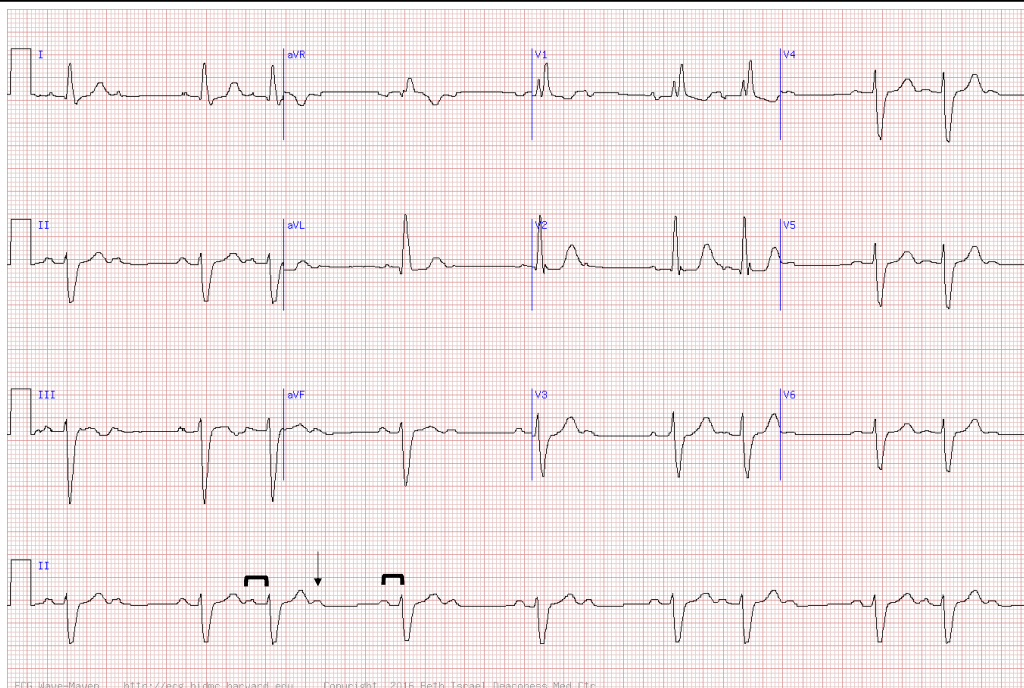




ECG Wave-Maven | <http://ecg.bidmc.harvard.edu> | Copyright, 2016 Beth Israel Deaconess Med Ctr

71

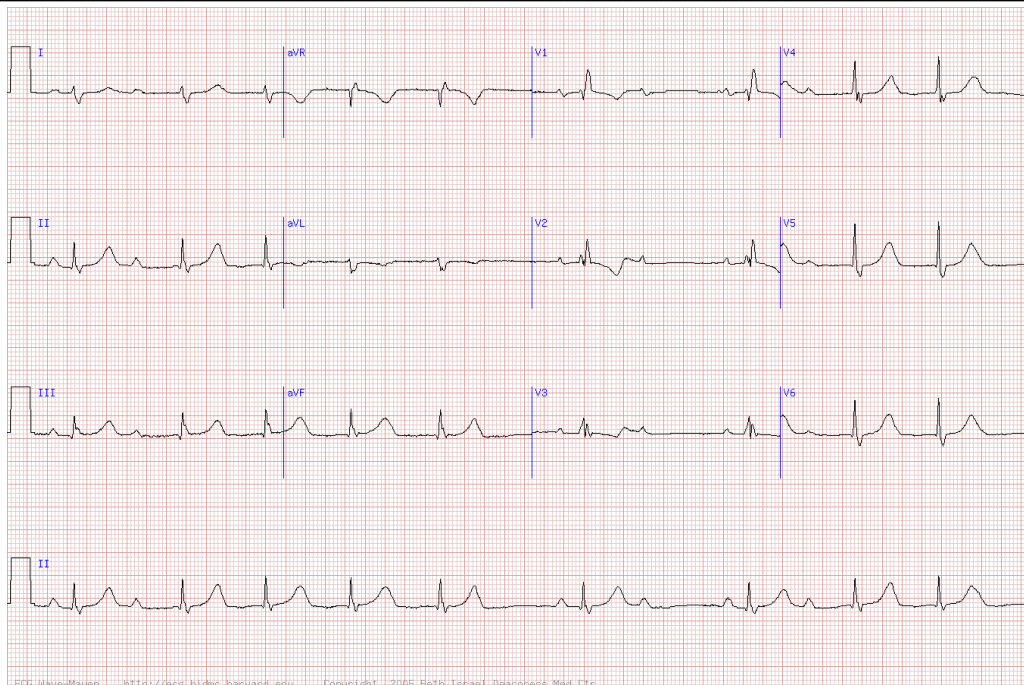
Nathanson LA et al. <http://ecg.bidmc.harvard.edu>.



ECG Wave-Maven | <http://ecg.bidmc.harvard.edu> | Copyright, 2016 Beth Israel Deaconess Med Ctr

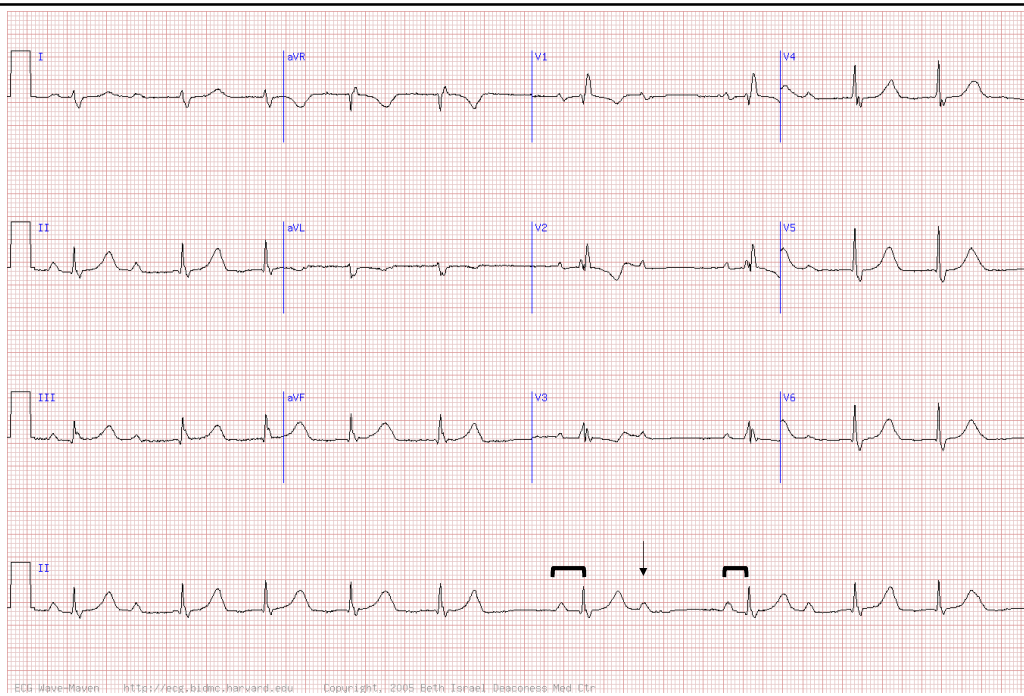
72

Nathanson LA et al. <http://ecg.bidmc.harvard.edu>.



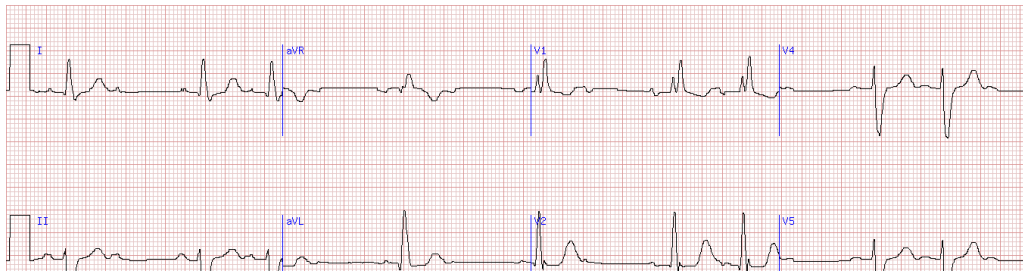
73

Nathanson LA et al. <http://ecg.bidmc.harvard.edu>.



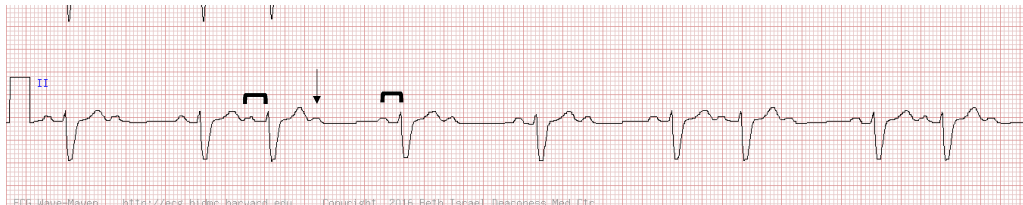
74

Nathanson LA et al. <http://ecg.bidmc.harvard.edu>.



The PR intervals before and after the non-conducted P-wave are about the same duration in Mobitz Type II 2nd Degree AV Block

Mobitz Type II 2nd Degree AV Block is an indication for PPM placement if no reversible causes are identified



ECG Wave-Maven | <http://ecg.bidmc.harvard.edu> | Copyright, 2015 Beth Israel Deaconess Med Ctr

75

Nathanson LA et al. <http://ecg.bidmc.harvard.edu>.

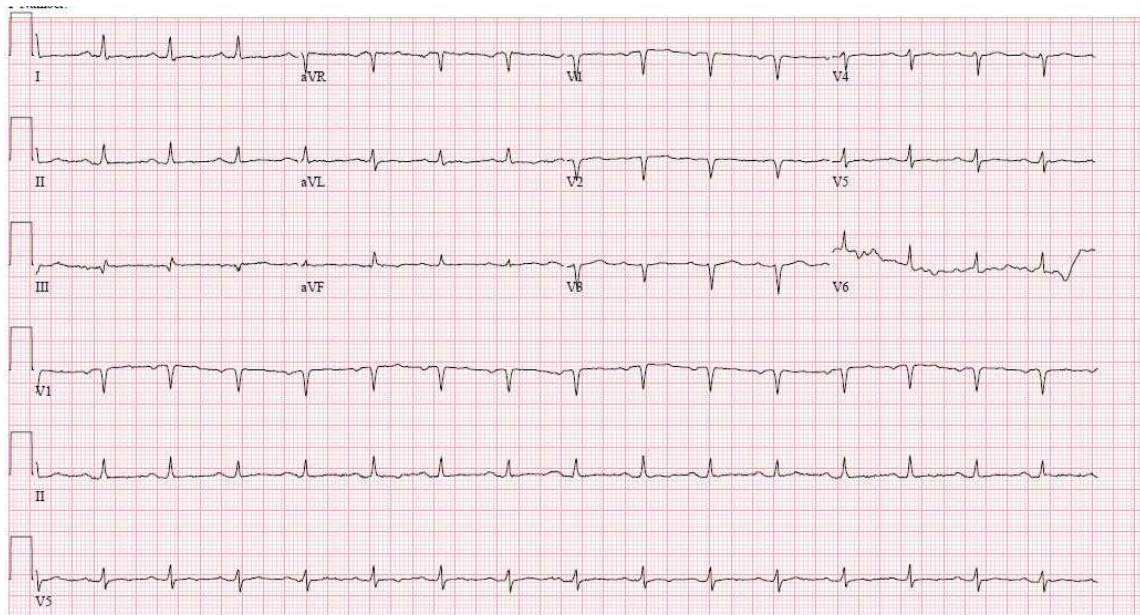
Case 11

A 33-year-old female with systemic lupus erythematosus presents to her rheumatologist's office with increased shortness of breath over the last two weeks. The examination is notable for tachycardia. An ECG is obtained. What is the likely etiology of the patient's shortness of breath based on the ECG?

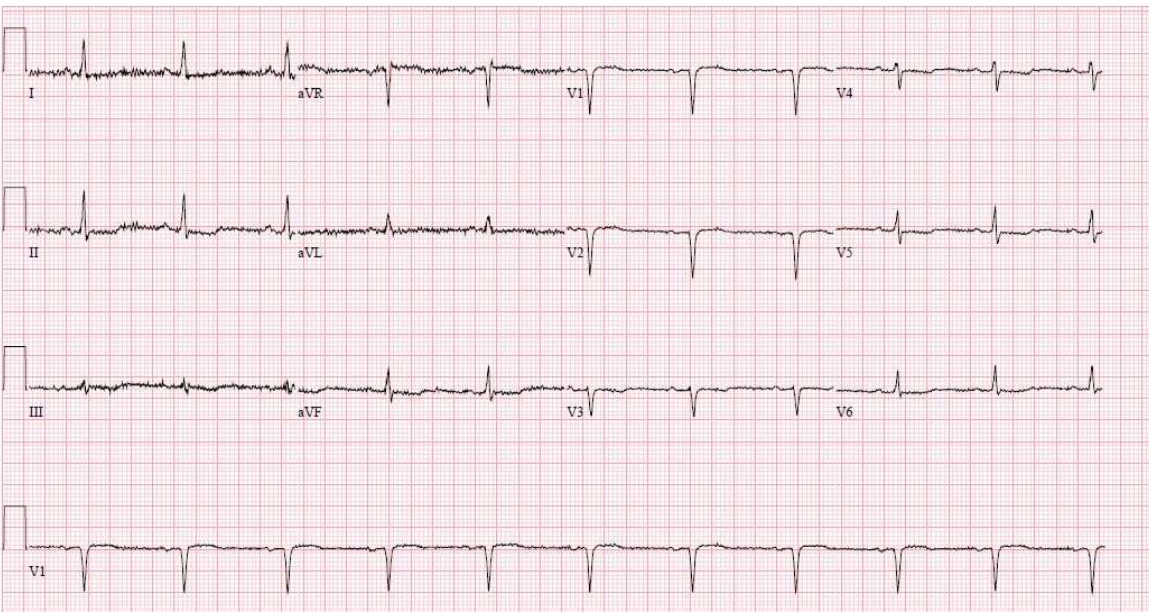1. Pulmonary embolism
2. Interstitial lung disease
3. Pericardial effusion
4. Ischemic heart disease



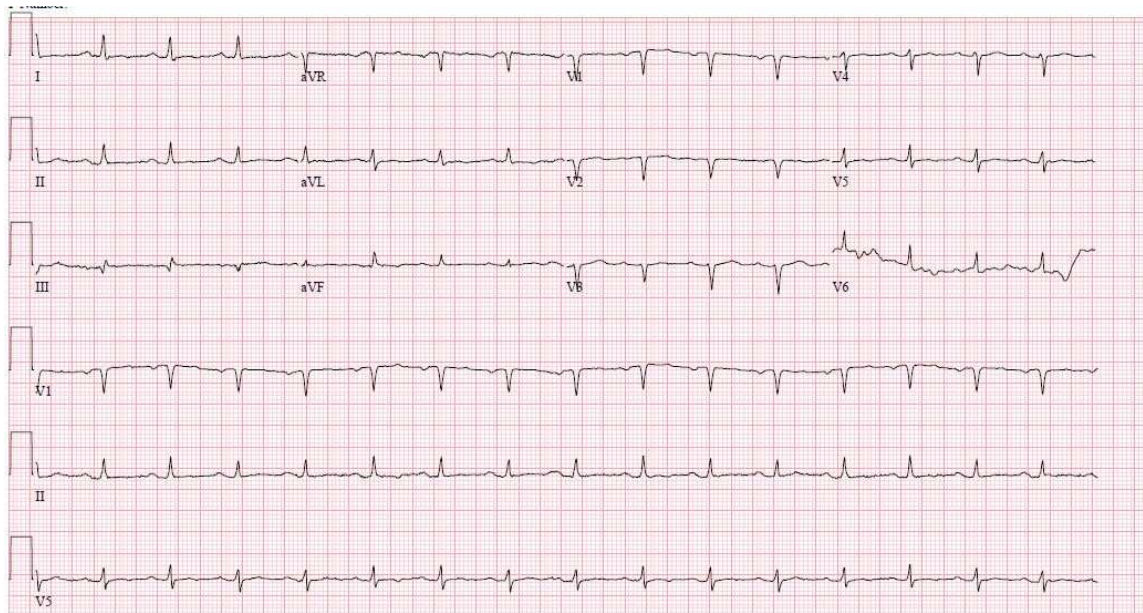
76



77



78



79

Case 11

A 33-year-old female with systemic lupus erythematosus presents to her rheumatologist's office with increased shortness of breath over the last two weeks. The examination is notable for tachycardia. An ECG is obtained. What is the likely etiology of the patient's shortness of breath based on the ECG?

1. Pulmonary embolism
2. Interstitial lung disease
3. Pericardial effusion
4. Ischemic heart disease



80

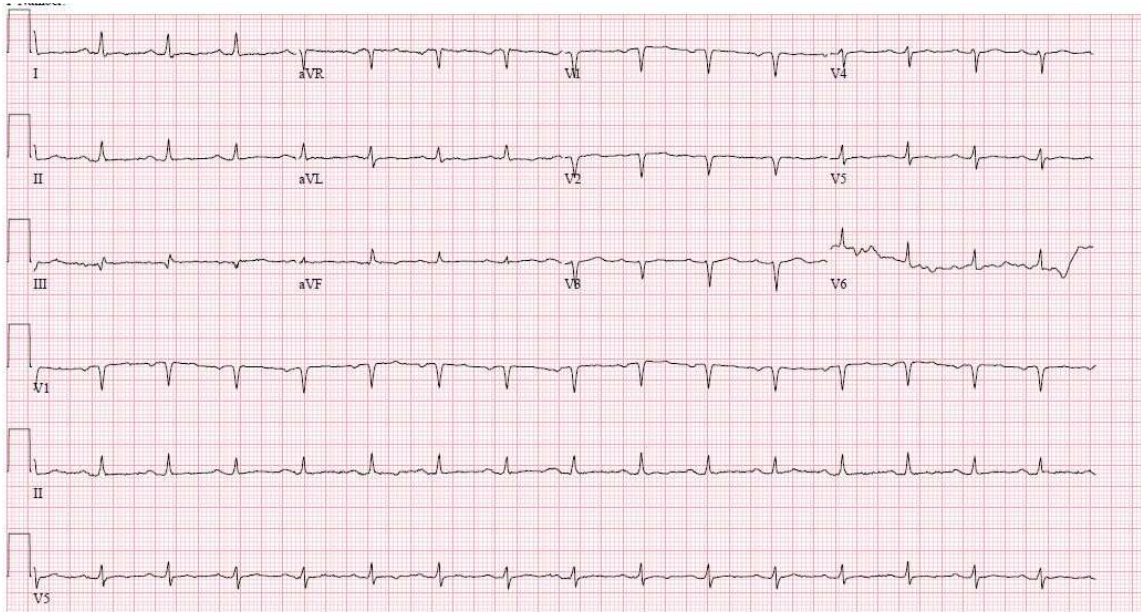
Case 11

A 33-year-old female with systemic lupus erythematosus presents to her rheumatologist's office with increased shortness of breath over the last two weeks. The examination is notable for tachycardia. An ECG is obtained. What is the likely etiology of the patient's shortness of breath based on the ECG?

1. Pulmonary embolism
2. Interstitial lung disease
3. **Pericardial effusion**
4. Ischemic heart disease



81



82

Low-Voltage

- QRS amplitude <5 mm in limb leads and <10 mm in the precordial leads



Low-Voltage

- QRS amplitude <5 mm in limb leads and <10 mm in the precordial leads
- Causes:
 - **Pericardial and pleural effusions**
 - **Infiltrative cardiomyopathy**
 - **Pulmonary disease**
 - **Hypothyroidism**
 - Constrictive pericardial disease
 - Diffuse myocardial necrosis or fibrosis
 - Normal variant



Electrical Alternans

- Alternating QRS amplitude from beat to beat on ECG



85

Rosenbaum DS et al. N Engl J Med. 1994 Jan 27;330(4):235-41.

Electrical Alternans

- Alternating QRS amplitude from beat to beat on ECG
- Causes:
 - **Pericardial effusion**
 - Supraventricular tachycardia
 - Wolff-Parkinson-White (WPW)
 - Ventricular tachycardia
 - Myocardial disease
 - Pneumothorax
 - Emphysema



86

Rosenbaum DS et al. N Engl J Med. 1994 Jan 27;330(4):235-41.

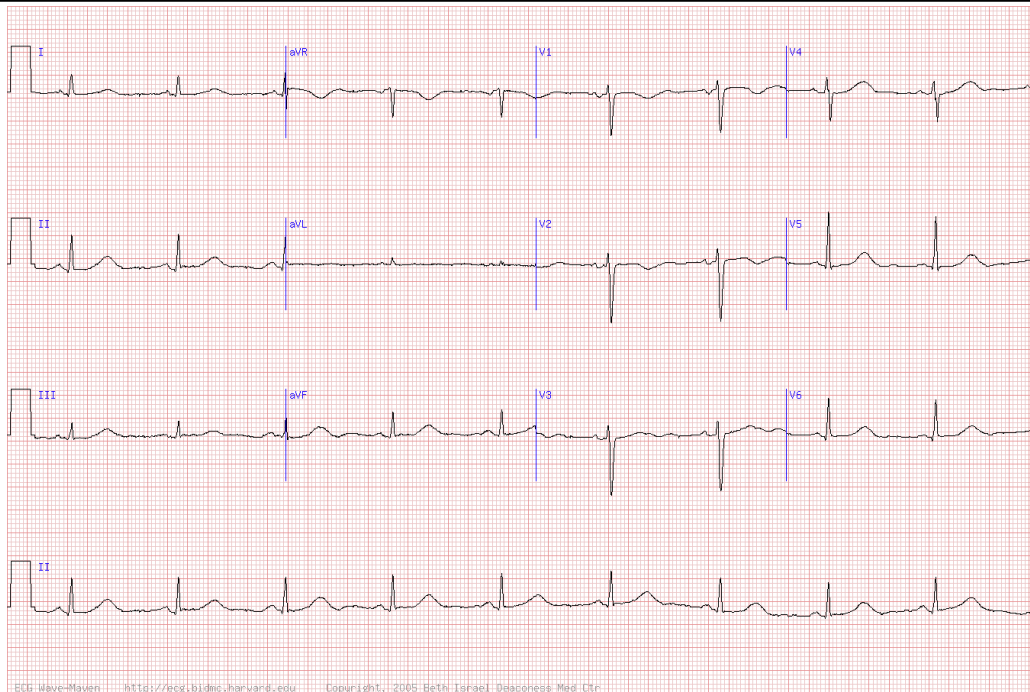
Case 12

A 32-year-old man with a history of schizophrenia and current tobacco use presents to an urgent care clinic due to palpitations. An ECG is obtained. This patient is at risk for developing which of the following?

1. Atrial fibrillation
2. Torsades de pointes
3. Ventricular tachycardia
4. AV block



87



88

Nathanson LA et al. <http://ecg.bidmc.harvard.edu>.

Case 12

A 32-year-old man with a history of schizophrenia and current tobacco use presents to an urgent care clinic due to palpitations. An ECG is obtained. This patient is at risk for developing which of the following?

1. Atrial fibrillation
2. Torsades de pointes
3. Ventricular tachycardia
4. AV block



Case 12

A 32-year-old man with a history of schizophrenia and current tobacco use presents to an urgent care clinic due to palpitations. An ECG is obtained. This patient is at risk for developing which of the following?

1. Atrial fibrillation
2. **Torsades de pointes**
3. Ventricular tachycardia
4. AV block



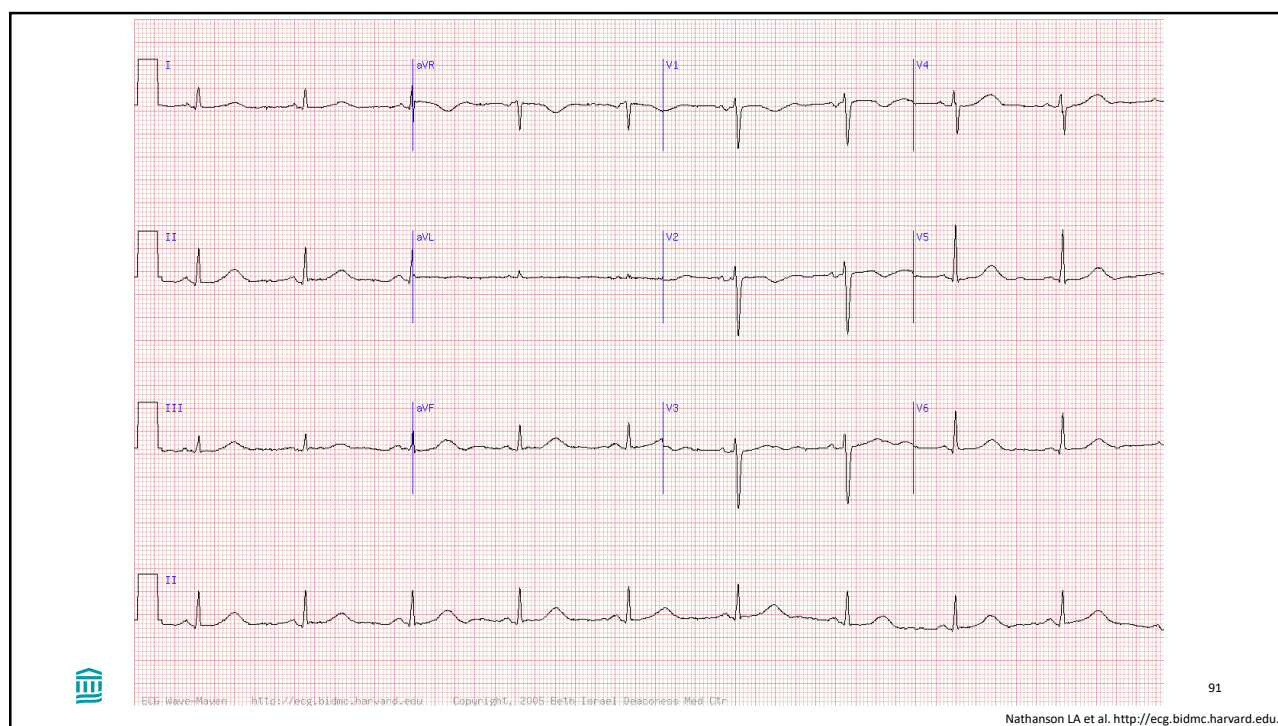


Table 1

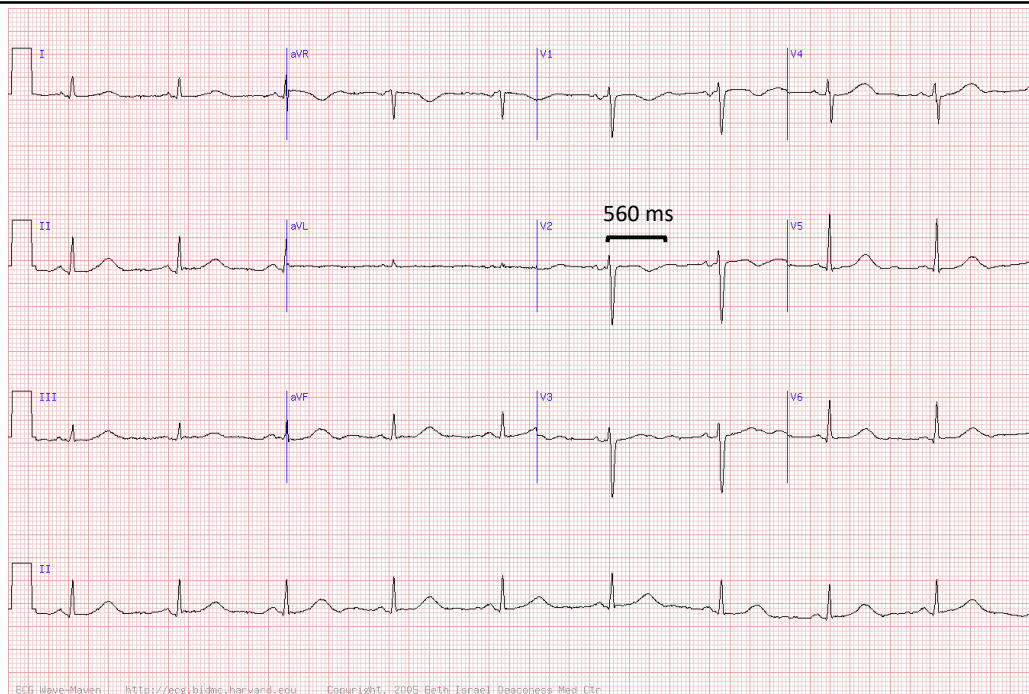
The current methods of QT correction and their mathematical formulas.

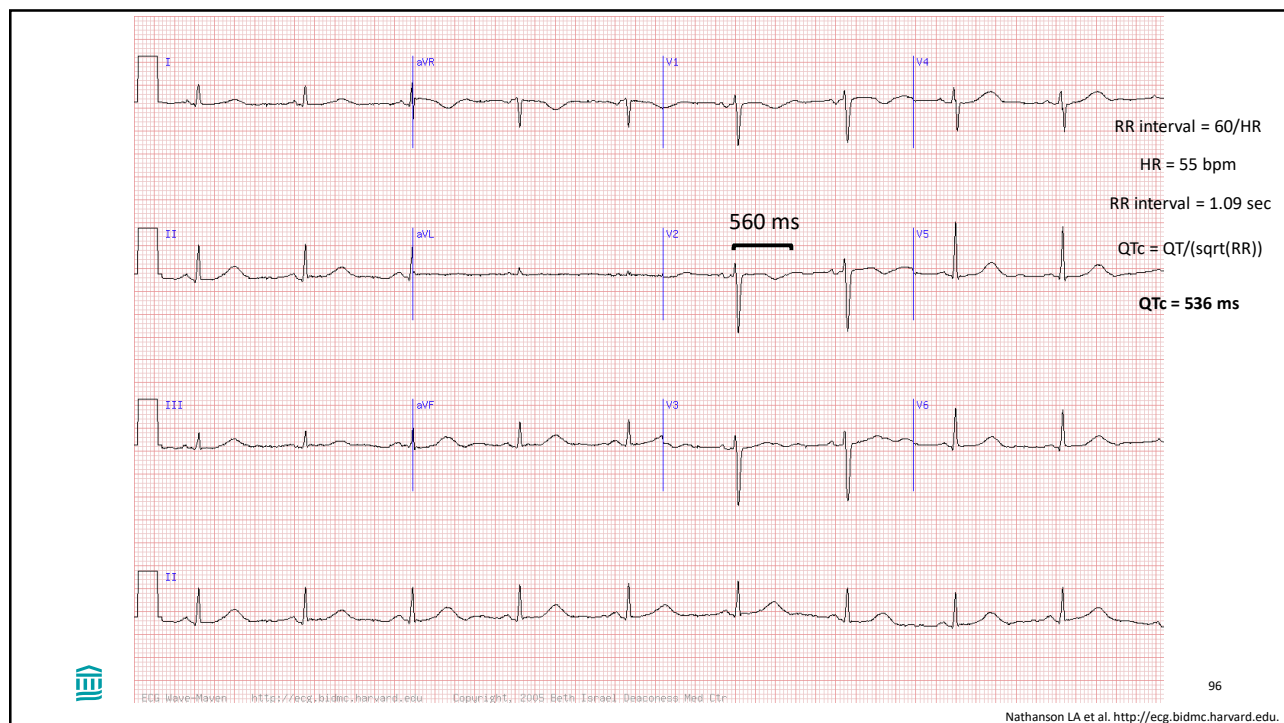
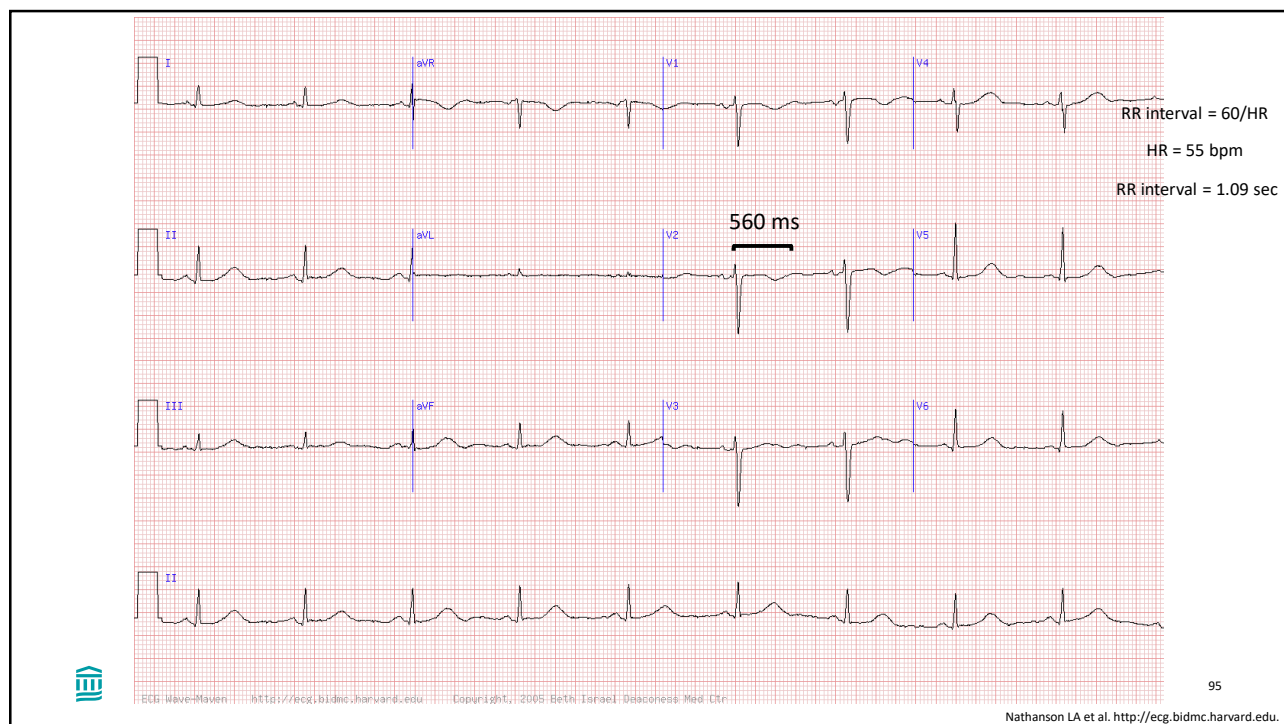
QT Correction (QTc)	Formula
1. Bazett	$QTcB = QT/RR^{1/2}$
2. Fridericia	$QTcFri = QT/RR^{1/3}$
3. Framingham	$QTcFra = QT + 0.154 (1-RR)$
4. Hodges	$QTcH = QT + 0.00175$

Table 1

The current methods of QT correction and their mathematical formulas.

QT Correction (QTc)	Formula
1. Bazett	$QTcB = QT/RR^{1/2}$
2. Fridericia	$QTcFri = QT/RR^{1/3}$
3. Framingham	$QTcFra = QT + 0.154 (1-RR)$
4. Hodges	$QTcH = QT + 0.00175$





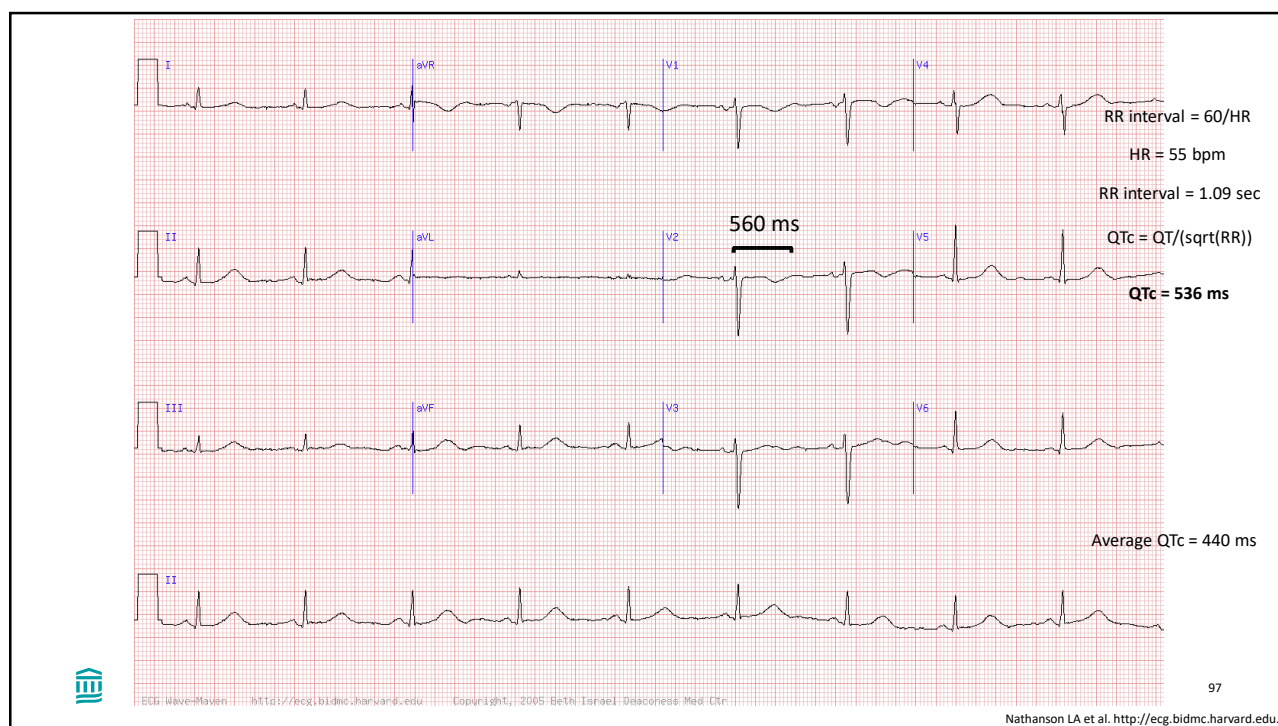


Table 3
Medications that prolong the QTc interval.

Medication category	Medications prolonging QTc	Implicated mechanism of QTc prolongation
Antipsychotics	Thioridazine, Pimozide, IV Haloperidol	Direct IKr channel antagonism [13]
Antiarrhythmics	Class IA (Quinidine)	Na ⁺ channel blockers: reentry arrhythmia [18]
	Class III (Sotalol, Amiodarone)	K ⁺ channel blockers: delayed repolarization [18]
Antibiotics	Macrolides (Erythromycin and Clarithromycin), Trimethoprim, Pentamidine, Azoles, Fluoroquinolones	Indirect IKr channel blockage and dispersion of repolarization [19,20]
Antiemetics	Ondansetron (Zofran), Granisetron	Potent IKr channel blockage [21]

IKr (rapidly-activating potassium currents); IV (intravenous); Na⁺ (sodium); K⁺ (potassium).

AHA/ACCF Scientific Statement

Prevention of Torsade de Pointes in Hospital Settings A Scientific Statement From the American Heart Association and the American College of Cardiology Foundation

*Endorsed by the American Association of Critical-Care Nurses, the International Society for
Computerized Electrocardiology, and the Heart Rhythm Society*

After initiation of a drug associated with TdP, ECG signs indicative of risk for arrhythmia include an **increase in QTc from pre-drug baseline of 60 ms** and marked **QTc interval prolongation >500 ms**



99

Drew BJ et al. Circulation 2010 Mar 2;121(8):1047-60.

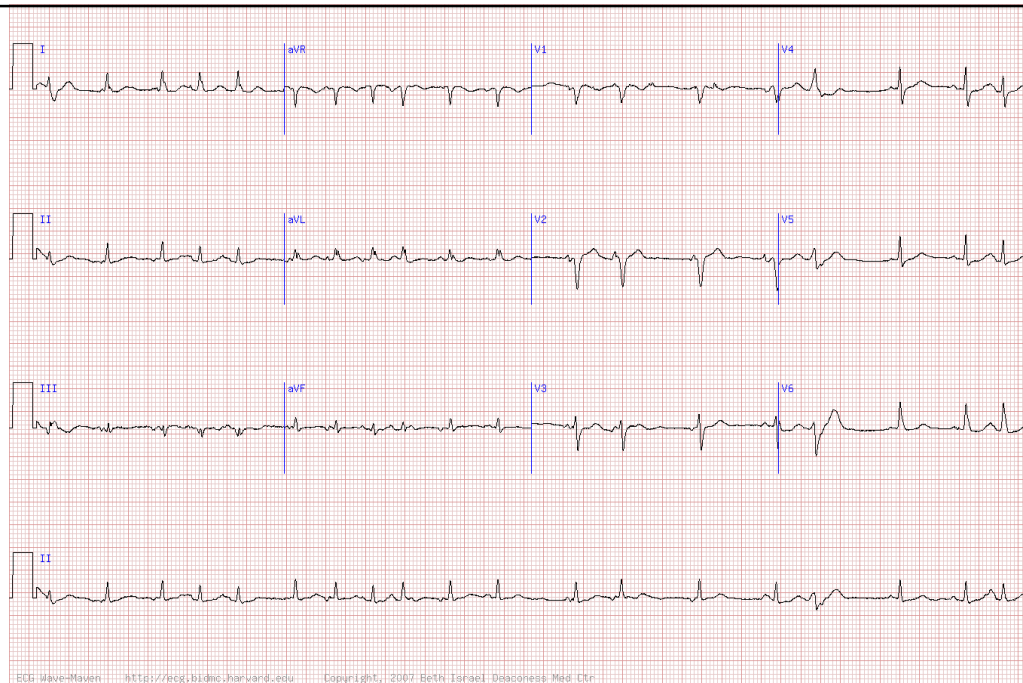
Case 13

A 76-year-old man with COPD is admitted to the medical ICU with urosepsis. What arrhythmia is present?

1. Atrial fibrillation
2. AVNRT
3. Multifocal atrial tachycardia
4. Sinus tachycardia with sinus arrhythmia



100



ECG WaveMaven <http://ecg.bidmc.harvard.edu> Copyright © 2007 Beth Israel Deaconess Med Ctr

101

Nathanson LA et al. <http://ecg.bidmc.harvard.edu>

Case 13

A 76-year-old man with COPD is admitted to the medical ICU with urosepsis. What arrhythmia is present?

1. Atrial fibrillation
2. AVNRT
3. Multifocal atrial tachycardia
4. Sinus tachycardia with sinus arrhythmia



102

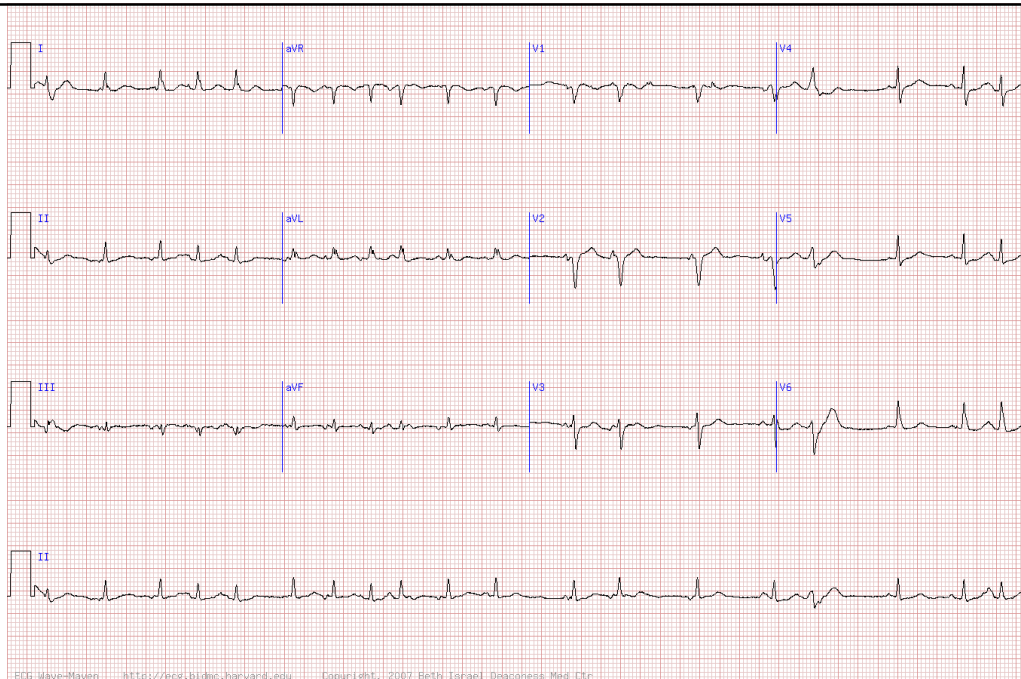
Case 13

A 76-year-old man with COPD is admitted to the medical ICU with urosepsis. What arrhythmia is present?

1. Atrial fibrillation
2. AVNRT
3. **Multifocal atrial tachycardia**
4. Sinus tachycardia with sinus arrhythmia



103



ECG Wave-Maven: <http://ecg.bidmc.harvard.edu/> Copyright, 2007 Beth Israel Deaconess Med. Ctr.

104

Nathanson LA et al. <http://ecg.bidmc.harvard.edu/>.

Multifocal Atrial Tachycardia

- SVT resulting in a rapid, irregular atrial rhythm that is caused by multiple ectopic foci within the atria
- Heart rate is > 100 beats per minute with organized atrial activity yielding three or more different non-sinus P-wave morphologies
- Typically seen in elderly patients with underlying chronic conditions, such as COPD
- If heart rate is ≤ 100 beats per minute, rhythm is called wandering atrial pacemaker



105

Custer AM et al. 2023.

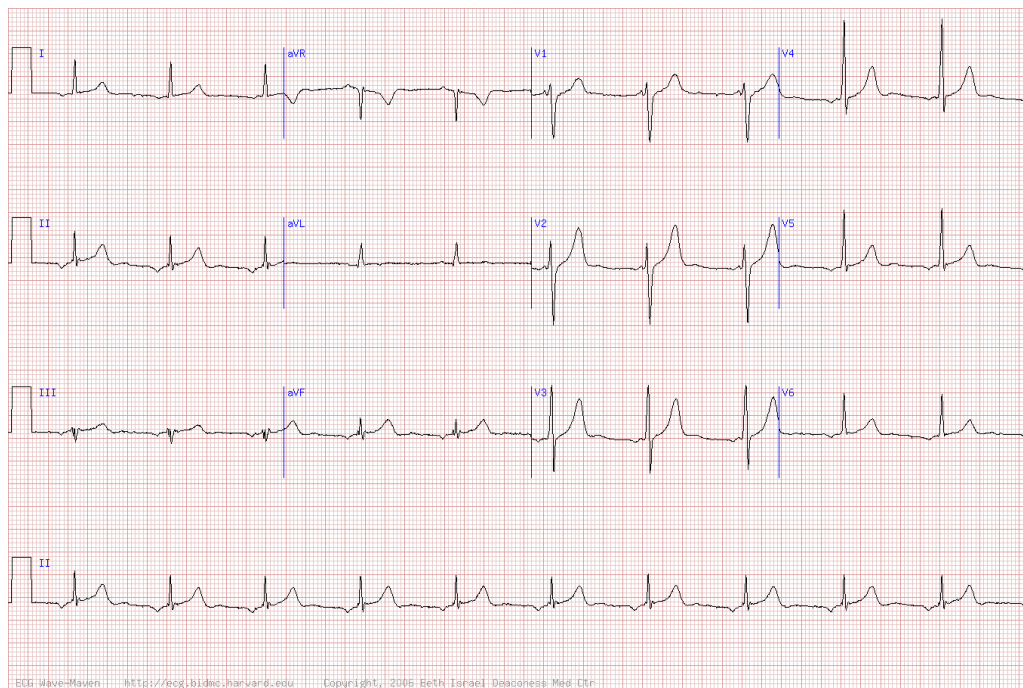
Case 14

A 42-year-old man is admitted to the general medicine service with cellulitis. An ECG is obtained due to a slow heart rate. What is the rhythm?

1. Ectopic atrial rhythm
2. Sinus rhythm
3. Atrial fibrillation
4. Junctional rhythm



106



107

Nathanson LA et al. <http://ecg.bidmc.harvard.edu>

Case 14

A 42-year-old man is admitted to the general medicine service with cellulitis. An ECG is obtained due to a slow heart rate. What is the rhythm?

1. Ectopic atrial rhythm
2. Sinus rhythm
3. Atrial fibrillation
4. Junctional rhythm



108

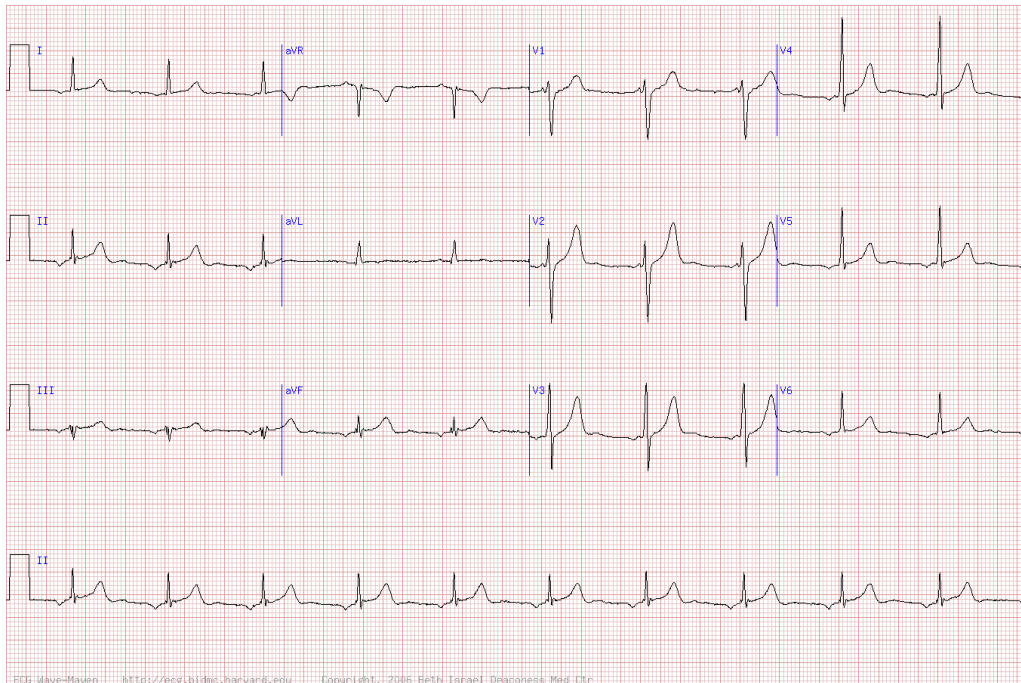
Case 14

A 42-year-old man is admitted to the general medicine service with cellulitis. An ECG is obtained due to a slow heart rate. What is the rhythm?

1. **Ectopic atrial rhythm**
2. Sinus rhythm
3. Atrial fibrillation
4. Junctional rhythm



109



110

ECG Wave-Maven: <https://ecg.bidmc.harvard.edu/> Copyright, 2016 Beth Israel Deaconess Med Ctr

Nathanson LA et al. <http://ecg.bidmc.harvard.edu>.

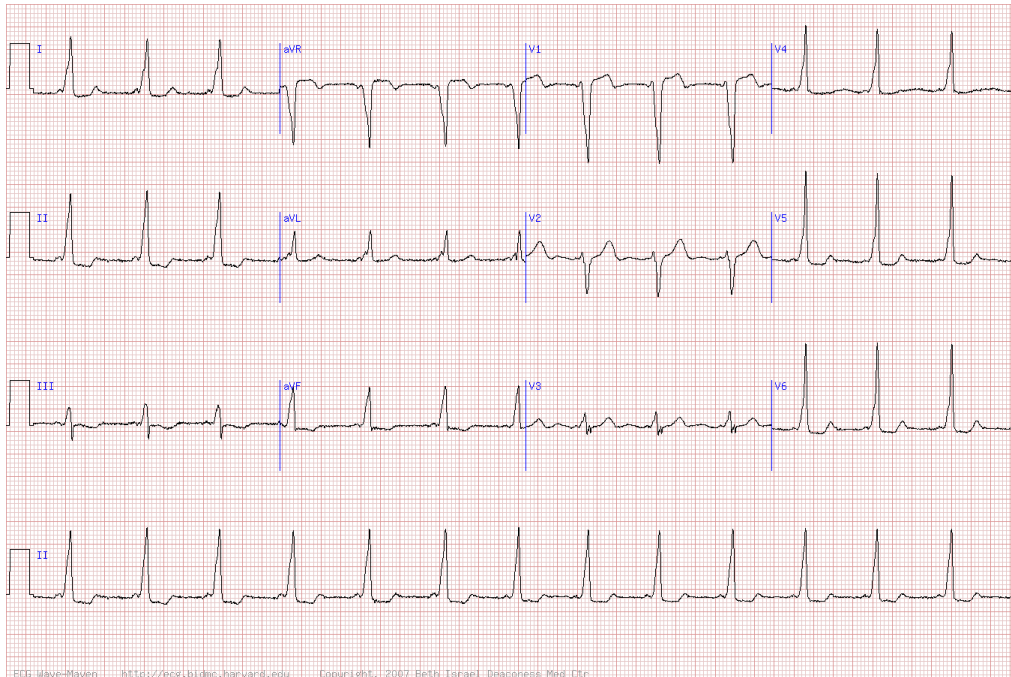
Case 15

A 31-year-old woman is admitted to the general medicine service due to recurrent syncope. What is the most important finding on the ECG?

1. Normal sinus rhythm
2. Left ventricular hypertrophy
3. Mobitz Type II 2nd Degree AV Block
4. Pre-excitation



111



ECG Wave-Maven - <http://ecg.bidmc.harvard.edu> - Copyright, 2007 Beth Israel Deaconess Med Ctr

112

Nathanson LA et al. <http://ecg.bidmc.harvard.edu>.

Case 15

A 31-year-old woman is admitted to the general medicine service due to recurrent syncope. What is the most important finding on the ECG?

1. Normal sinus rhythm
2. Left ventricular hypertrophy
3. Mobitz Type II 2nd Degree AV Block
4. Pre-excitation

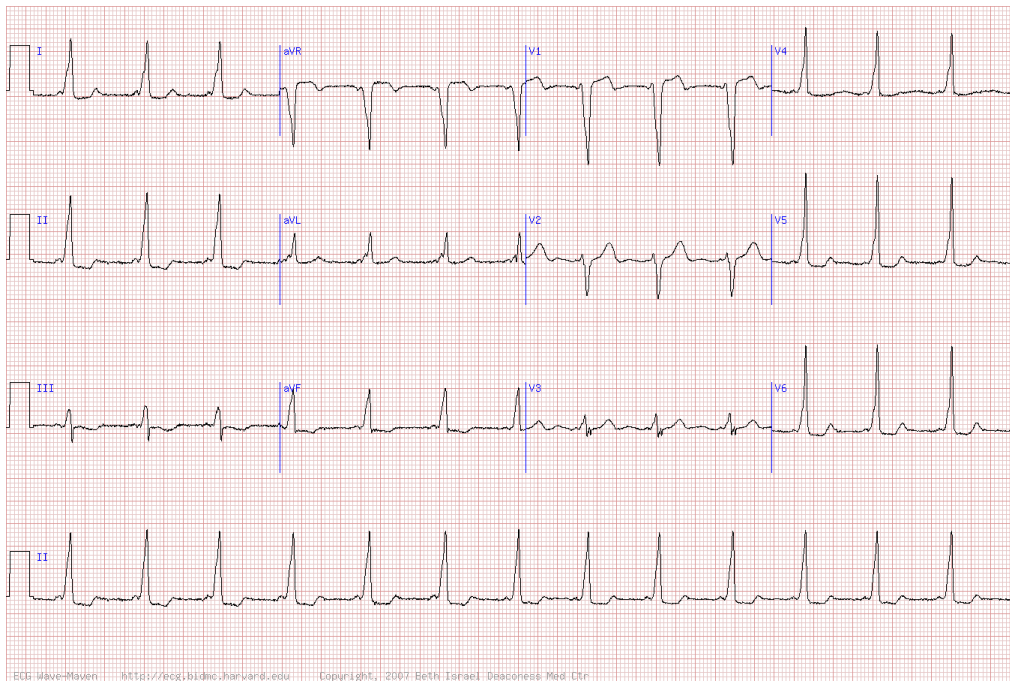


Case 15

A 31-year-old woman is admitted to the general medicine service due to recurrent syncope. What is the most important finding on the ECG?

1. Normal sinus rhythm
2. Left ventricular hypertrophy
3. Mobitz Type II 2nd Degree AV Block
4. **Pre-excitation**

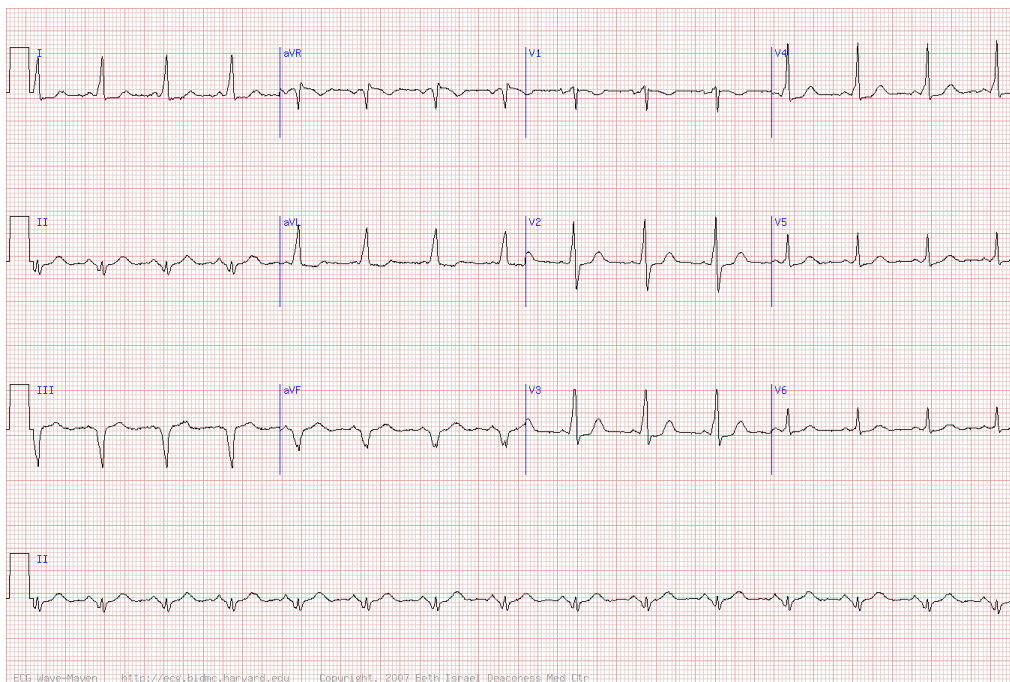




ECG Wave-Maven <http://ecg.bidmc.harvard.edu> Copyright, 2007 Beth Israel Deaconess Med Ctr

115

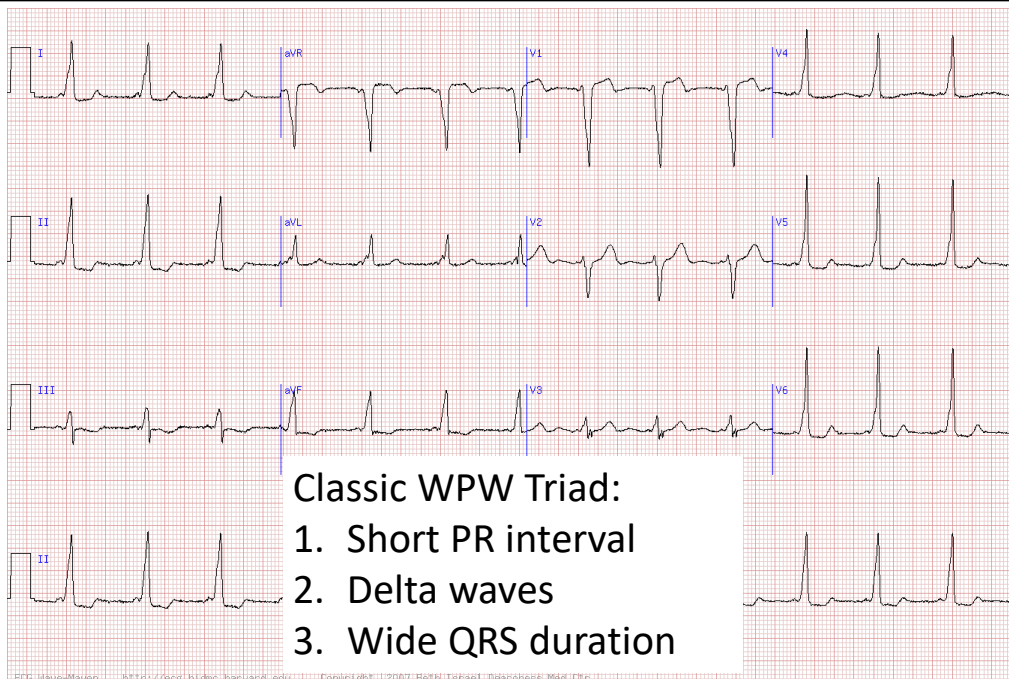
Nathanson LA et al. <http://ecg.bidmc.harvard.edu>.



ECG Wave-Maven <http://ecg.bidmc.harvard.edu> Copyright, 2007 Beth Israel Deaconess Med Ctr

116

Nathanson LA et al. <http://ecg.bidmc.harvard.edu>.



ECG Wave-Maven | <http://ecg.bidmc.harvard.edu> | Copyright © 2007 Beth Israel Deaconess Medical Center

117

Nathanson LA et al. <http://ecg.bidmc.harvard.edu>.

Thank You

- Dale S. Adler, MD
- Leonard S. Lilly, MD
- Nathanson LA, McClennen S, Safran C, Goldberger AL. ECG Wave-Maven: Self-Assessment Program for Students and Clinicians. <http://ecg.bidmc.harvard.edu>.



118